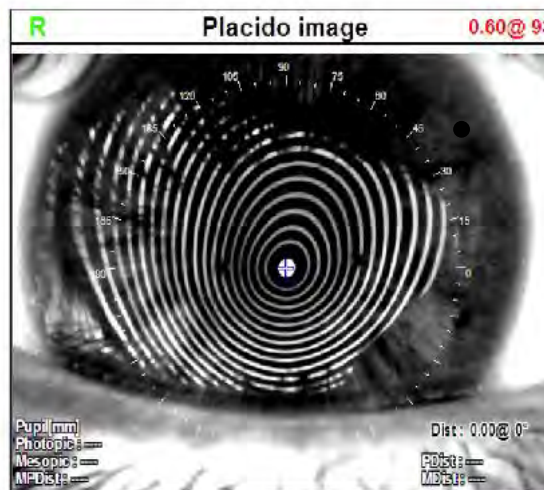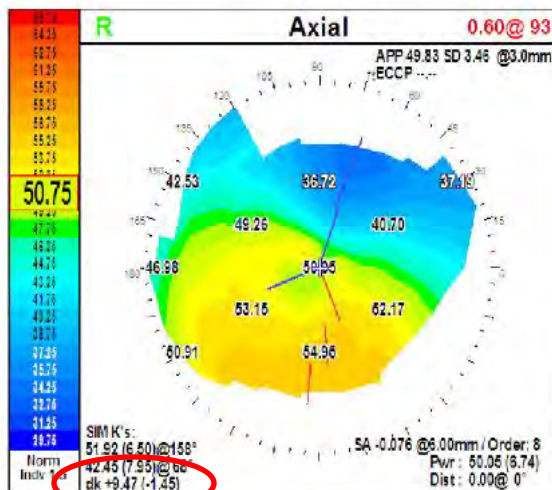
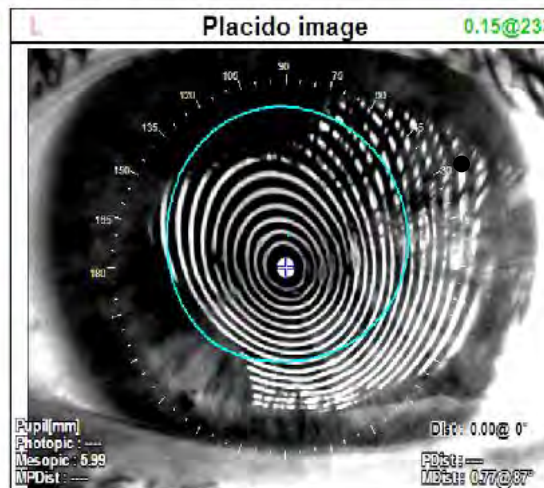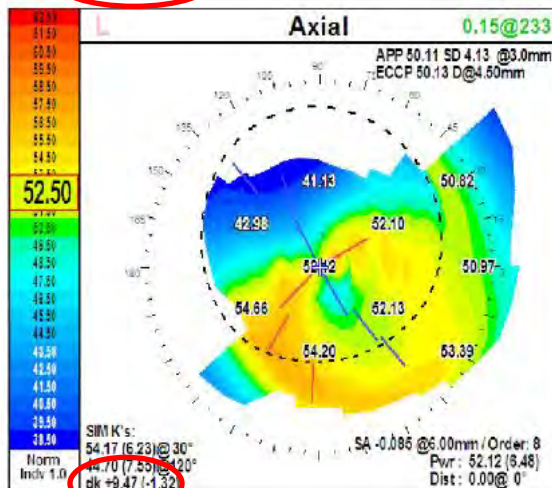


Case #1: 52 yo m Pellucid Marginal Degeneration (PMD) both eyes

L	06/07/2017 08:59	Comment	L	Diagnosis	L
R	06/07/2017 08:59		R		R



OD: -8.75+9.0x158 20/50



OS: -9.0+8.0x30 20/50

Case #1: Now 60 yo m Pellucid Marginal Degeneration (PMD) both eyes

Right eye: 9/2019 Cataract ext w trulign (crystalens) IOL

3/2019 removed running suture

10/2017 DALK 10.0mm bed/10.5mm donor 24 bite running suture

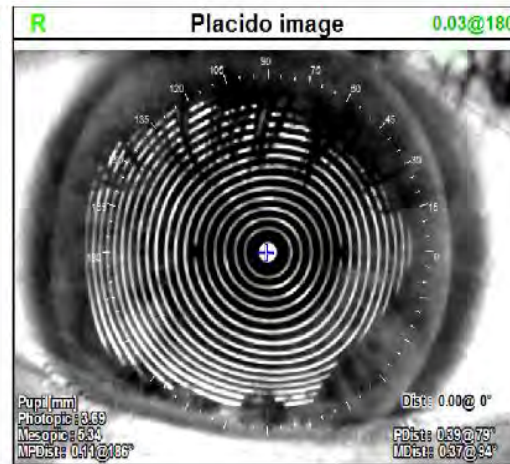
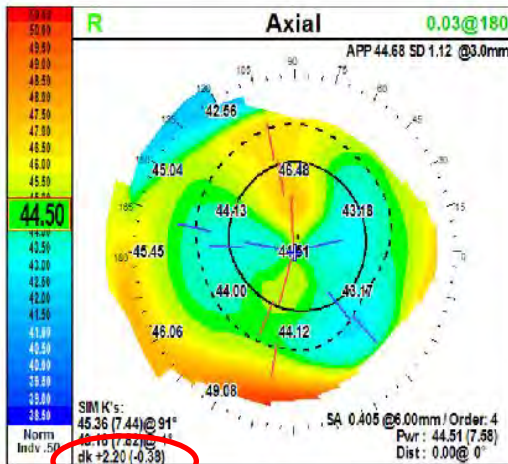
Left eye: 9/2019 Cataract ext w trulign (crystalens) IOL

7/2018 removed running suture

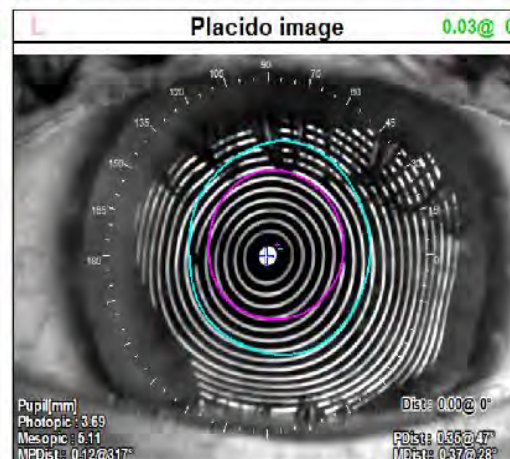
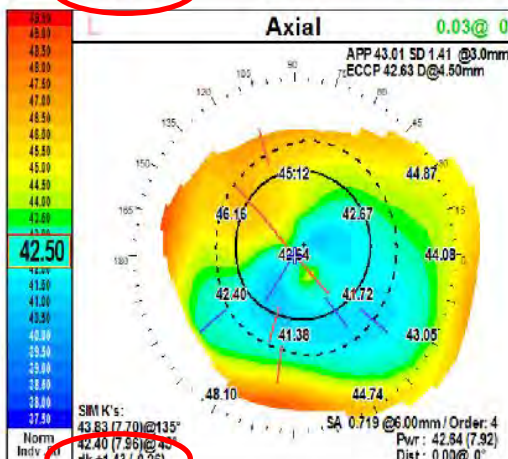
7/2017 DALK 10.0mm bed/10.0mm donor 24 bite running suture

Date	L	02/07/2025 10:56	Comment	L		Diagnosis	L	
	R	02/07/2025 10:56		R			R	

2/7/2025 Wears NO corrective lenses!



Uncorrected VA 20/40
-1.0+0.25x75 20/20



Uncorrected VA 20/40
-0.75+1.5x155 20/20

Case #1: Testimonial:


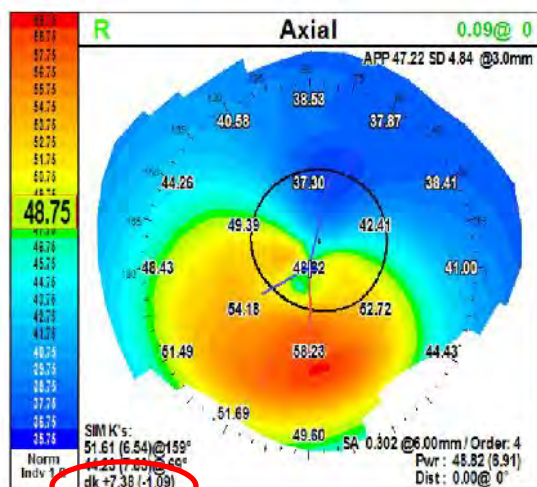
2/2025 now age 60... 8 yrs after large dia DALK OU



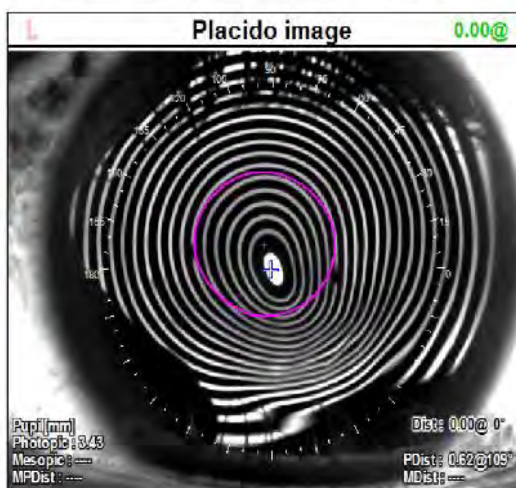
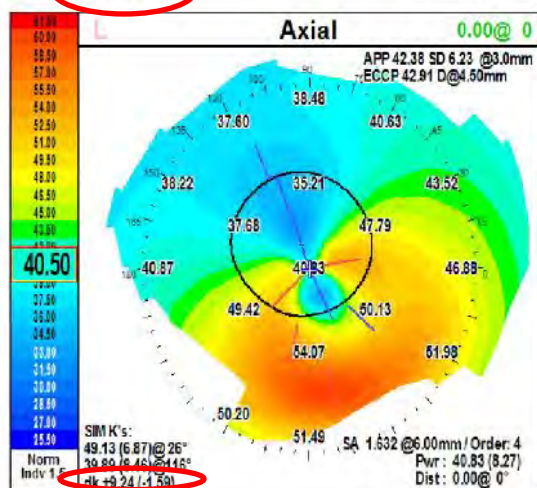
<https://youtube.com/shorts/4tIW0VhPHCI>

Case #2: 48 yo m Pellucid Marginal Degeneration (PMD) both eyes

10/21/2019 10:23		Comment	10/21/2019 10:23		Diagnosis
L	10/21/2019 10:23		R	10/21/2019 10:23	



OD: -6.50+7.25x172 20/50



OS: -4.0 + 5.50 x 26 20/30

Case #2:

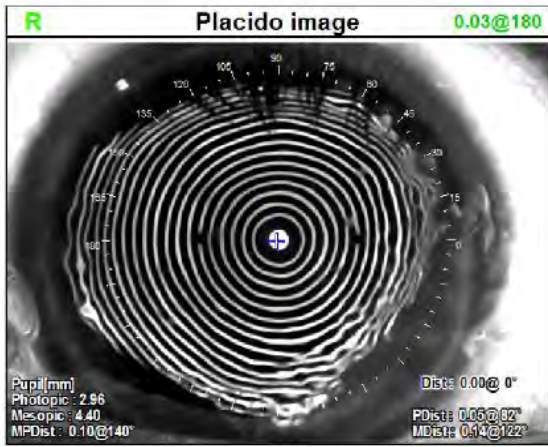
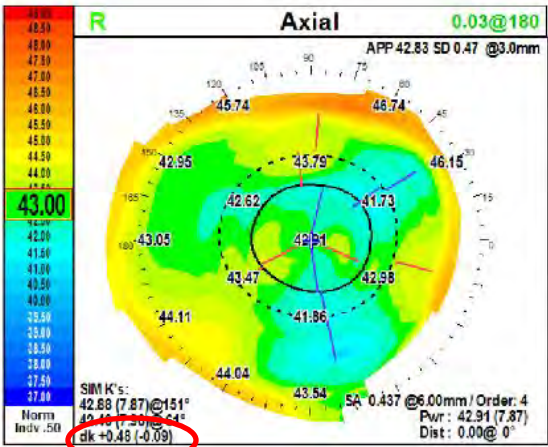
Pellucid Marginal Degeneration (PMD) both eyes

2021 running corneal graft sutures out OU

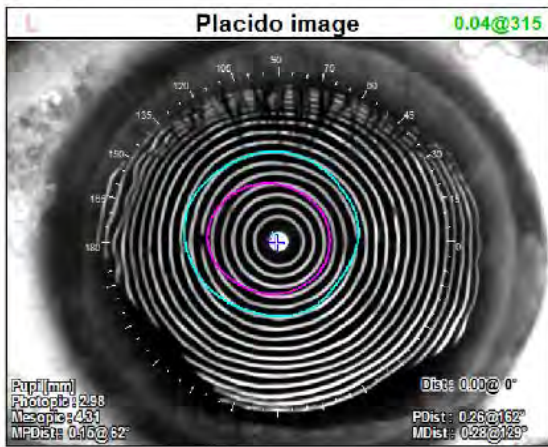
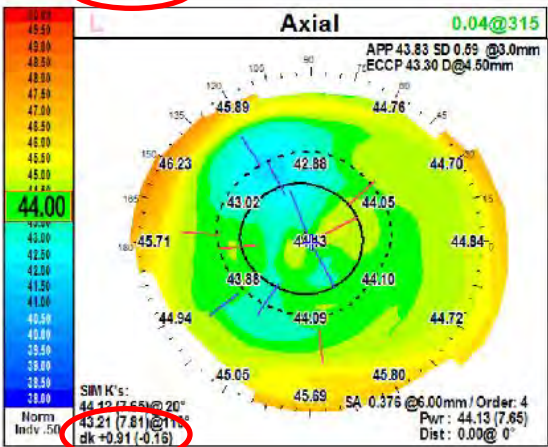
OD: 11/2020 DALK 10.25mm bed/10.5mm donor

OS: 12/2019 DALK 10.25mm bed/10.5mm donor

R	10/02/2023 13:59	Comment	R	Diagnosis	R
L	10/02/2023 13:59		L		L



10/2/2023
OD: --1.75+1.25x20 20/20



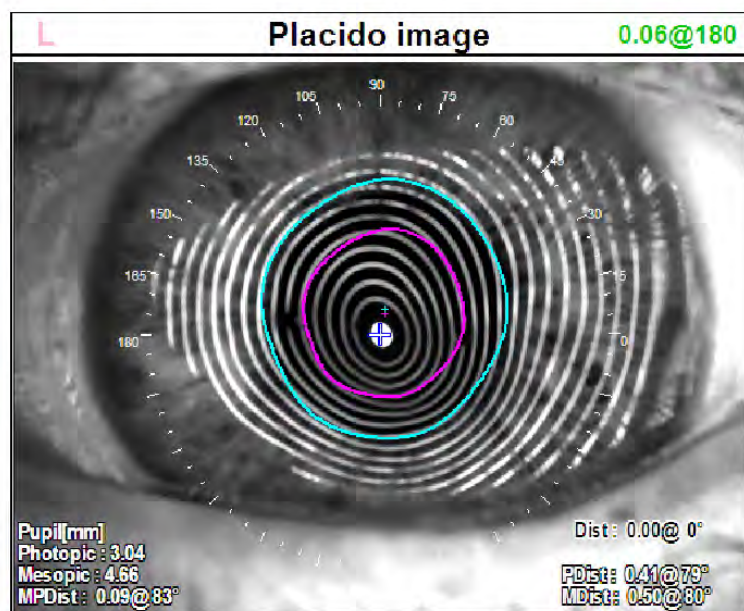
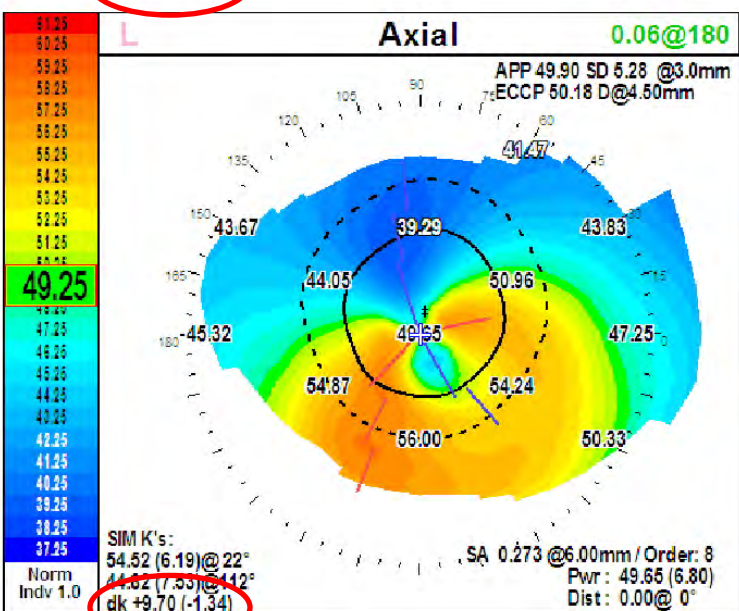
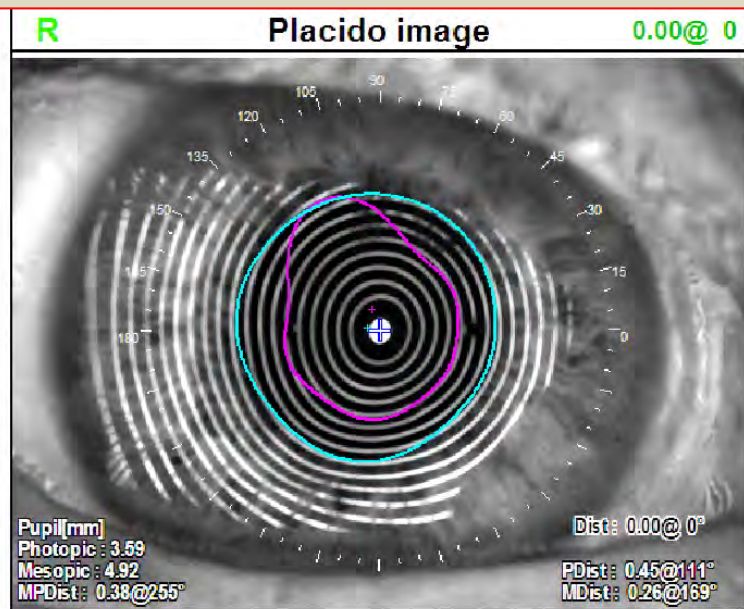
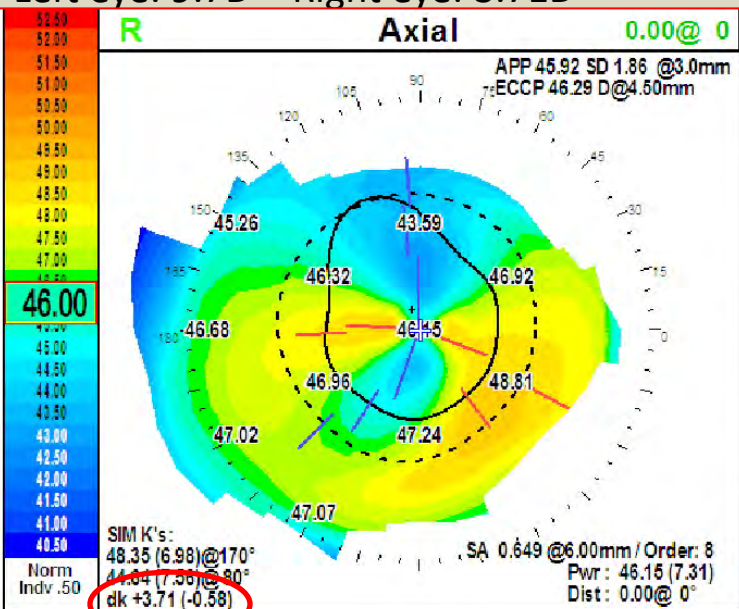
OS: -3.50+1.25x14 20/20

Case #3: 68 yo Pellucid Marginal Degeneration – both eyes

2018 Cornea Cross Linking OS – (performed elsewhere) “failed to improve my vision” (refused CXL OD)

Note: irregular astigmatism both eyes with High Cylinder magnitude

Left eye: 9.7D > Right eye: 3.71D



Case#3 Pellucid Marginal Degeneration

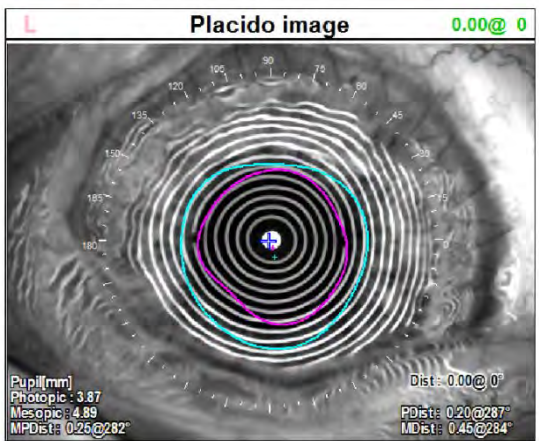
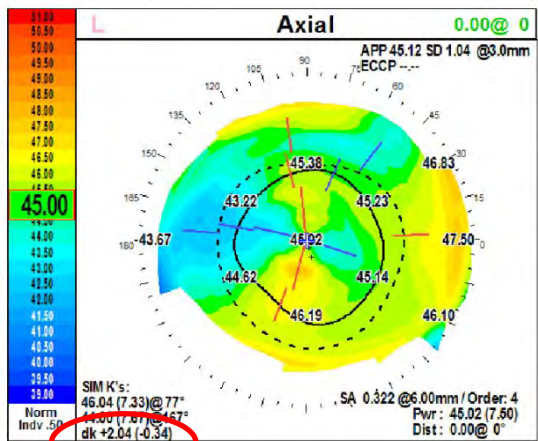
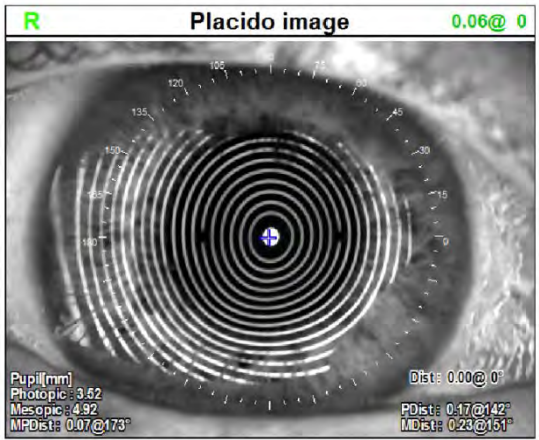
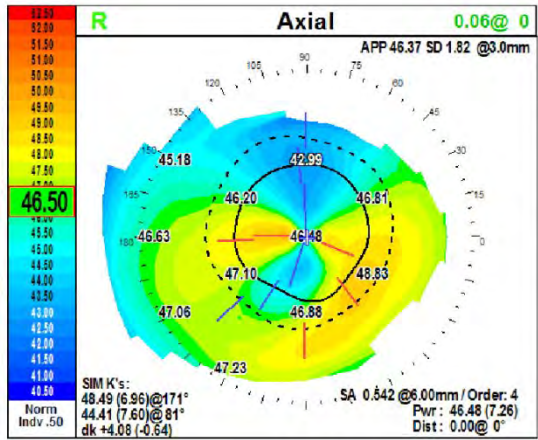
Left:

1/2020 topography below. Running suture “in”

2/2019 Dr Erdey DALK 9.5mm dia.

2018 Cornea Cross Linking – performed elsewhere “failed to improve my vision”

Date	L	01/23/2020 08:50	Comment	L		Diagnosis	L	
	R	01/23/2020 08:50		R			R	



Case#3 Pellucid Marginal Degeneration (PMD) – after Treatment:

Right: 4/2021: Cataract Ext high toric IOL Dr Erdey: Cylinder 4D (DALK not necessary):

Left: 5/2022 Topo (below) high suture-out cylinder in DALK graft ... but regular

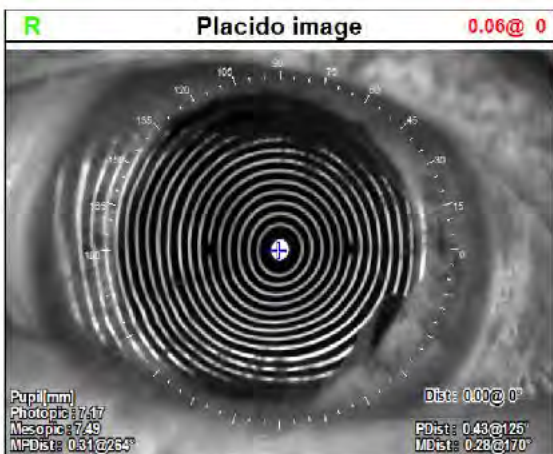
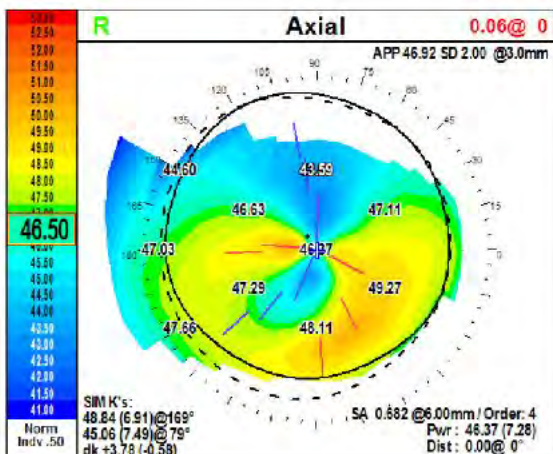
4/2021: Dr Erdey: Cataract Ext high (600) toric IOL x 65.

1/2021: Removed running corneal suture

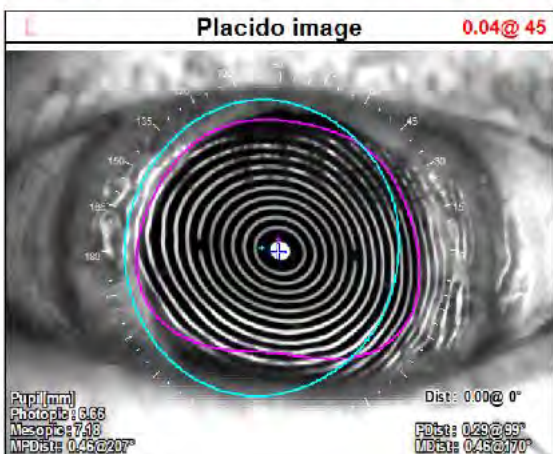
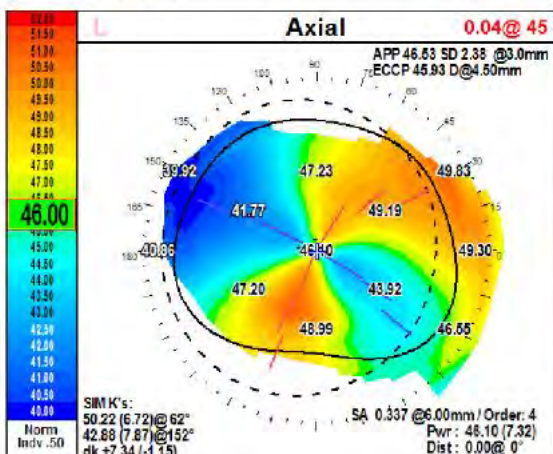
2/2019 Dr Erdey DALK 9.5mm dia. (corneal restoration)

2013 Cornea Cross Linking – performed elsewhere “failed to improve my vision”

L	05/18/2022 09:04	Comment	L	Diagnosis	L
R	05/18/2022 09:03		R		R



Uncorrected VA 20/25
VERY HAPPY!



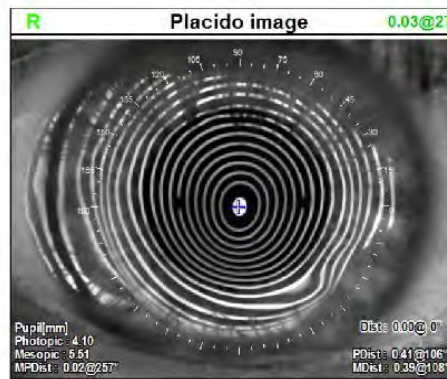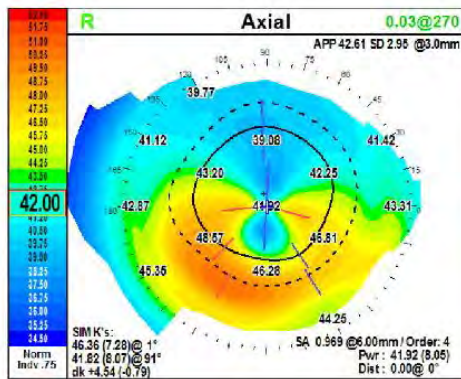
Uncorrected VA 20/25
-0.75+0.5x105 20/25
VERY HAPPY!

Case #4 poor vision, CL intolerant.

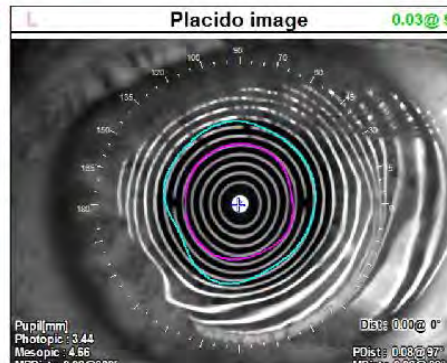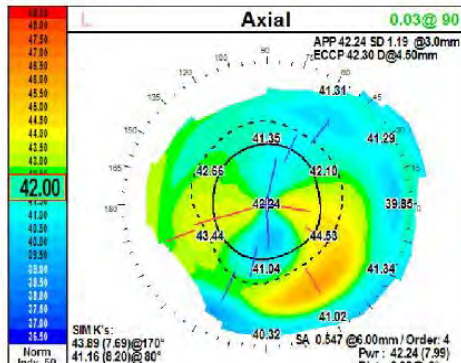
64 yo male Pellucid Marginal Degeneration OD worse then OS

2007 Intacs OU

L	12/29/2022 09:20	Comment	L	Diagnosis	L
R	12/29/2022 09:20		R		R



OD: -6.0+4.75x177 20/40



OS: -2.50+1.0x 165 20/30

Case #4 LAL for final optical rescue

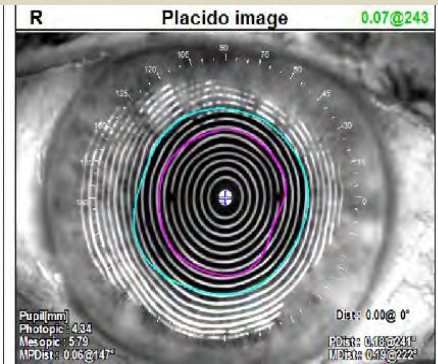
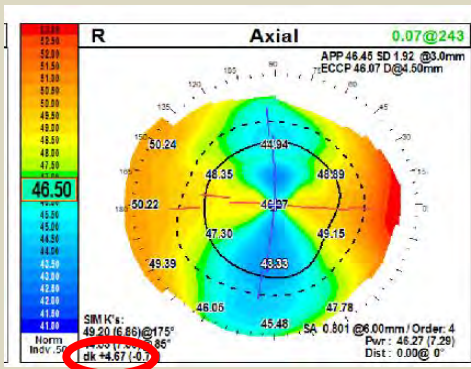
Right Eye

64 yo male Pellucid Marginal Degeneration

8/10/23 removed running cornea graft suture

2/14/23 removed Intacs/DALK 10.0mm bed/10.5mm donor

2007 Intacs



10/26/23 topography (Left upper)

- OD -14.0 +6.0 x 173 20/40

1/16/24 AK paired scleral tunnel x 180



3/20/24 topography (left lower): note reduced astigmatism

- OD -13.5+1.25 x 160 20/60

7/2/24 cataract ext with LAL for optical rescue



OD near plano, Uncorrected VA 20/25!!
(after all Light Delivery Device treatments completed)

