

Large Diameter DALK for Corneal Restoration of  
Radial Keratotomy(RK) - induced corneal ectasia  
case studies – long term follow up

Richard Erdey, MD  
Erdey Searcy Eye Group  
Columbus, OH

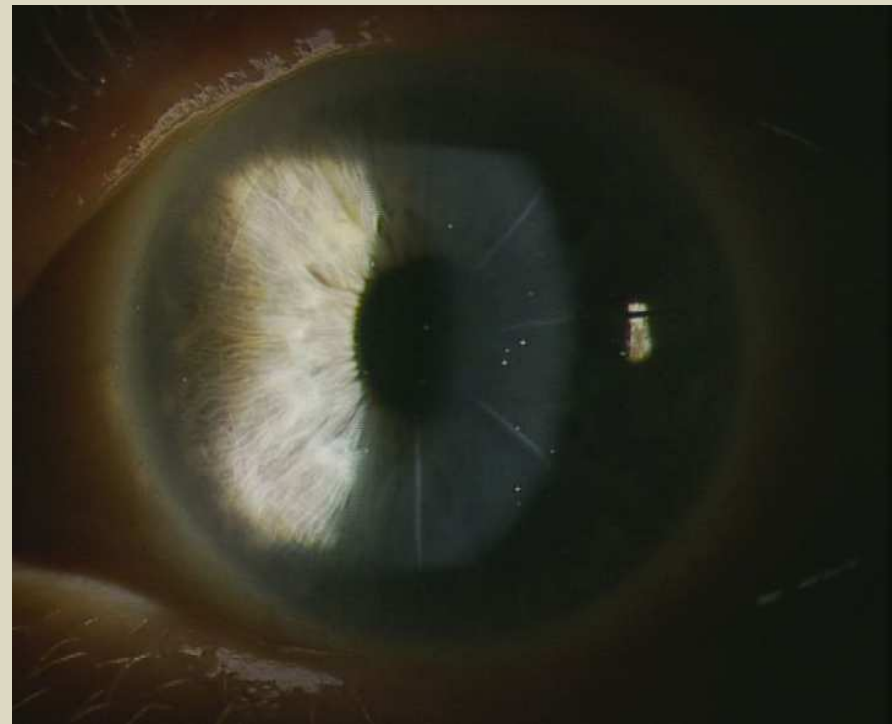
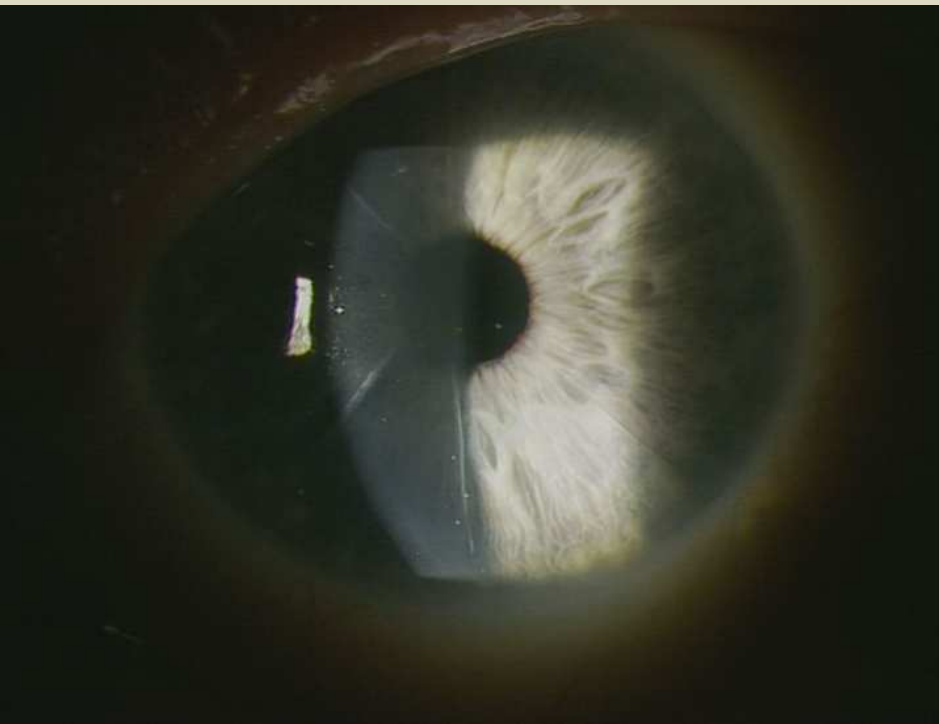
# Large Diameter DALK for Corneal Restoration of Radial Keratotomy(RK) - induced corneal ectasia case studies – long term follow

- 13 eyes of 7 patients
- 3mos-14 years follow up

Case #1: 64yo

Radial Keratotomy(RK)-induced ectasia, progressive hyperopia both eyes

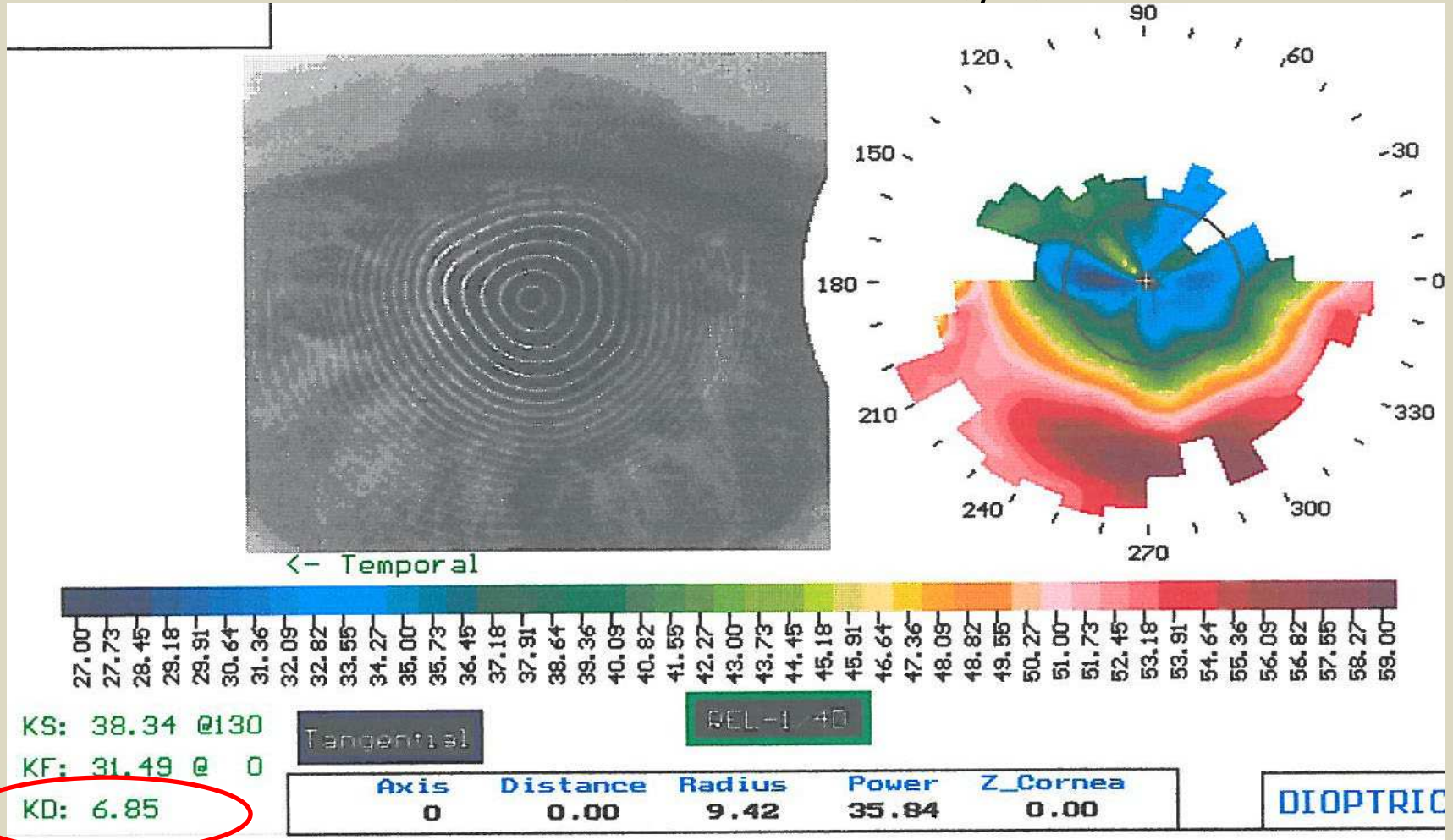
Note: RK corneal scars



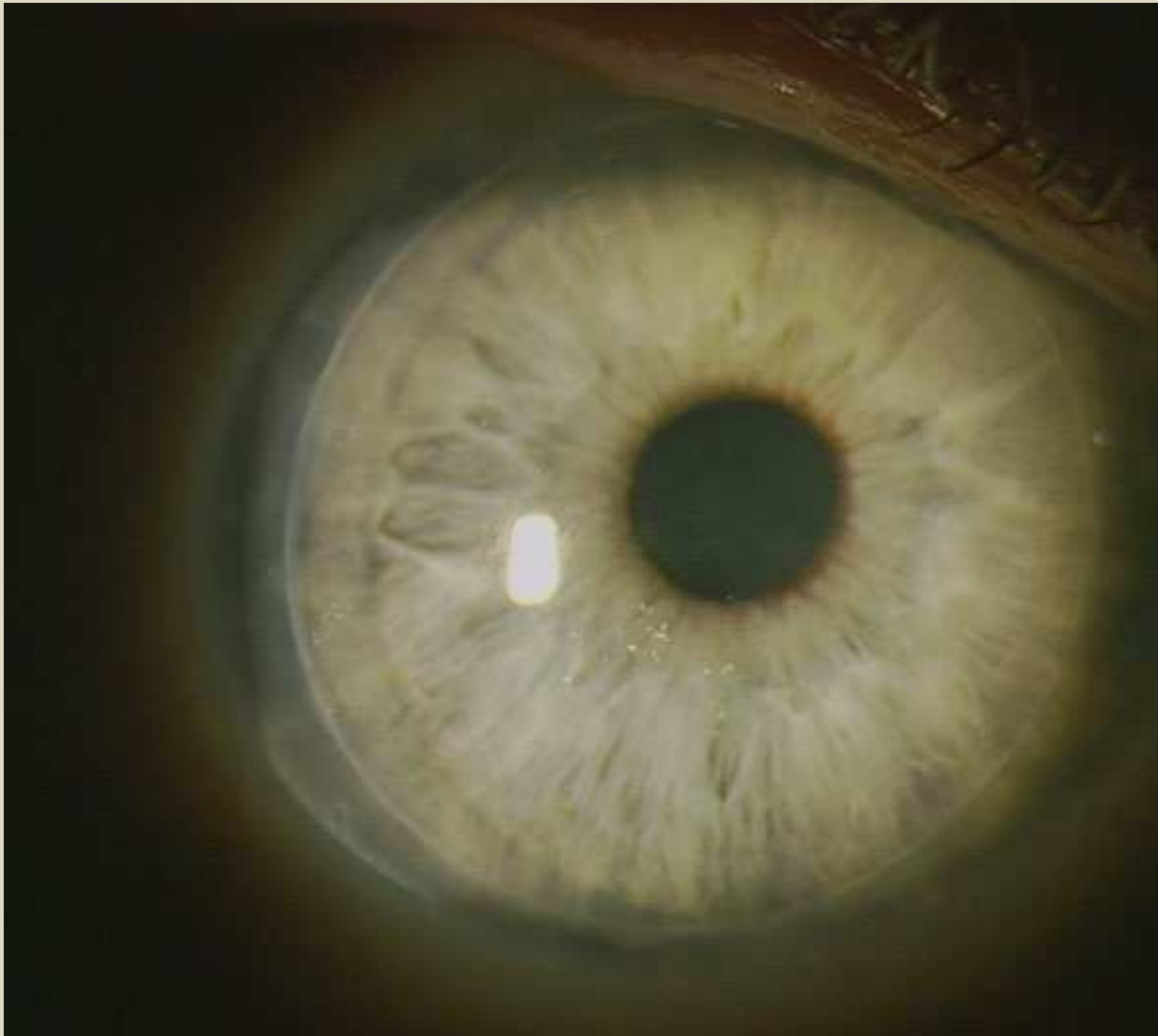
# Right Eye Pre-op

64 year old with cataract and RK-induced cornea ectasia  
Progressive hyperopia, irregular astigmatism

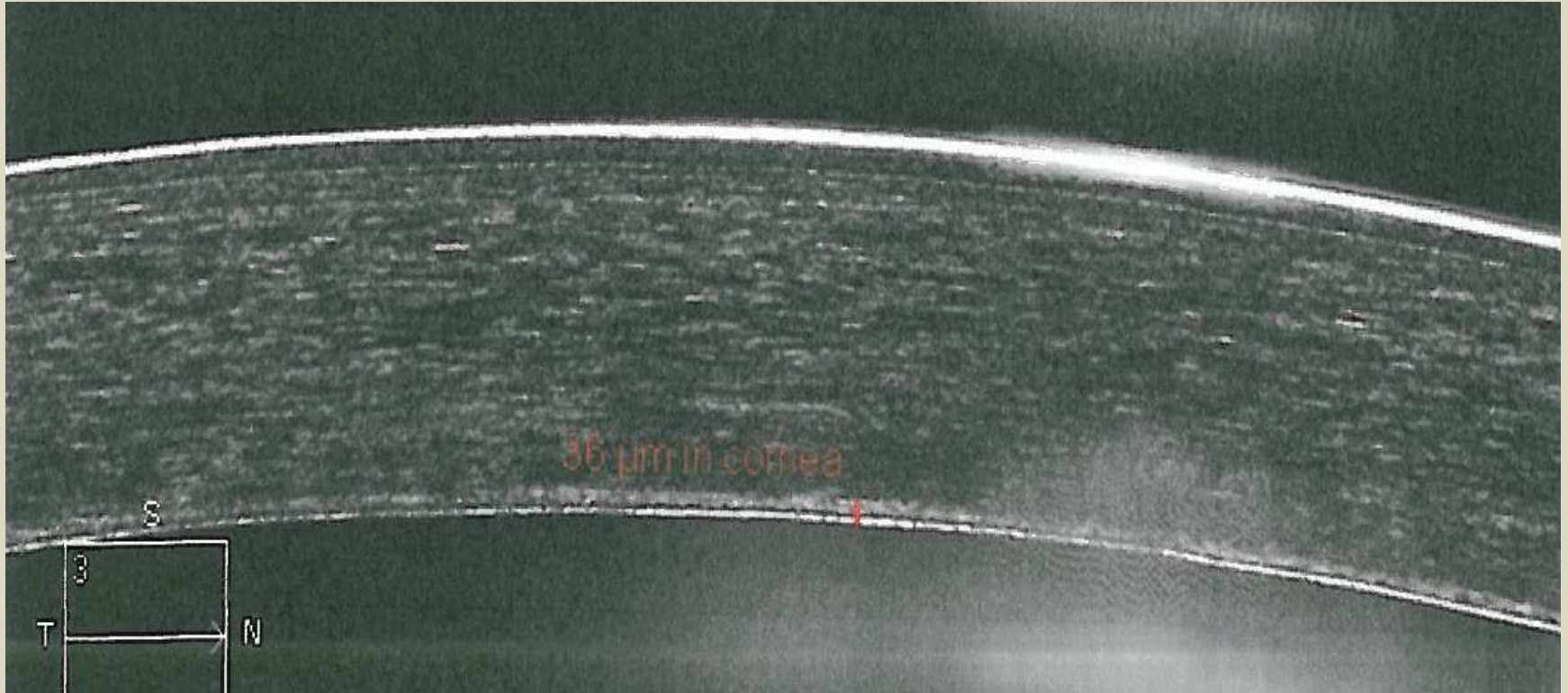OD: +7.25 + 2.25 x 137 20/70



Right Eye: Running suture removed: 7 mos after DALK



Right Eye: (OCT) 7 mos after DALK OD-manual dissection  
Note: 36u homogenous residual stromal bed



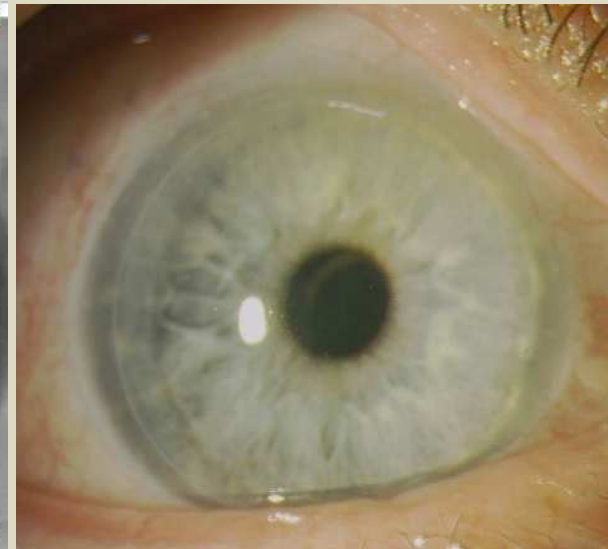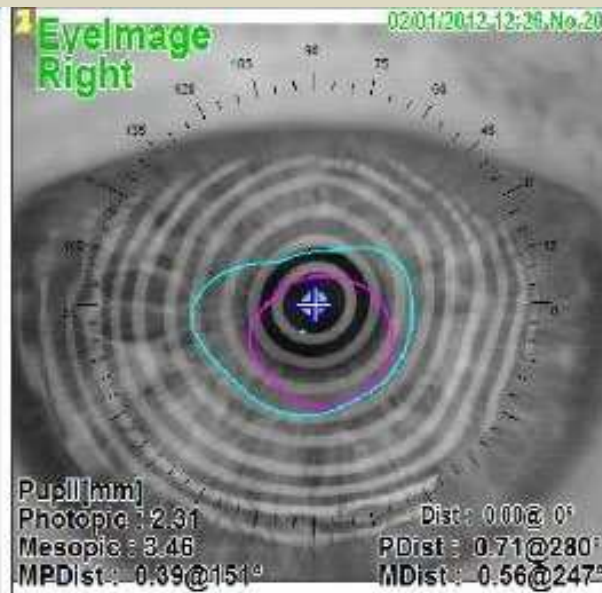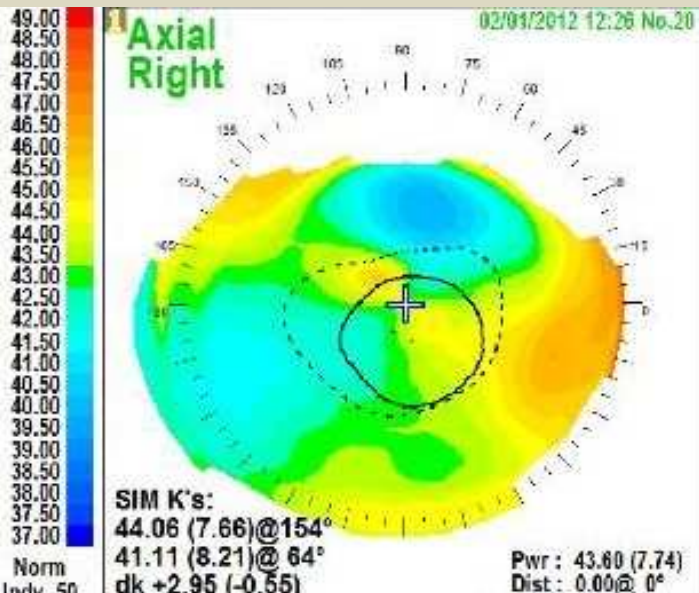
## RIGHT EYE

3 yrs after DALK (10mm diameter)

2 yrs after cat extraction with Alcon SN6AT5 IOL

Uncorrected Distance VA remains 20/20- plano !

Demonstrates EXCELLENT long-term refractive stability!



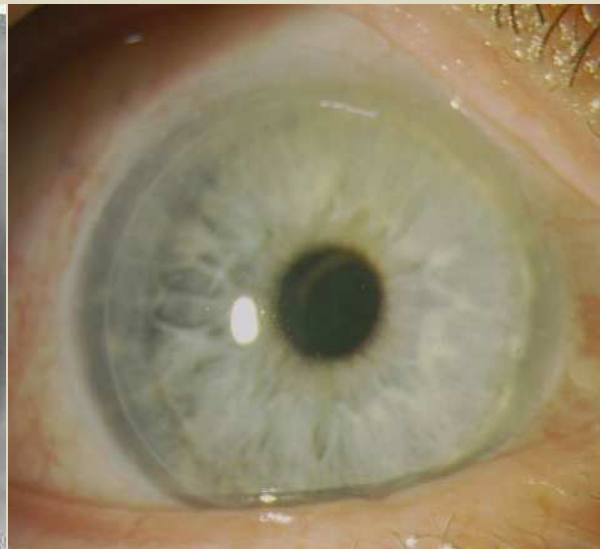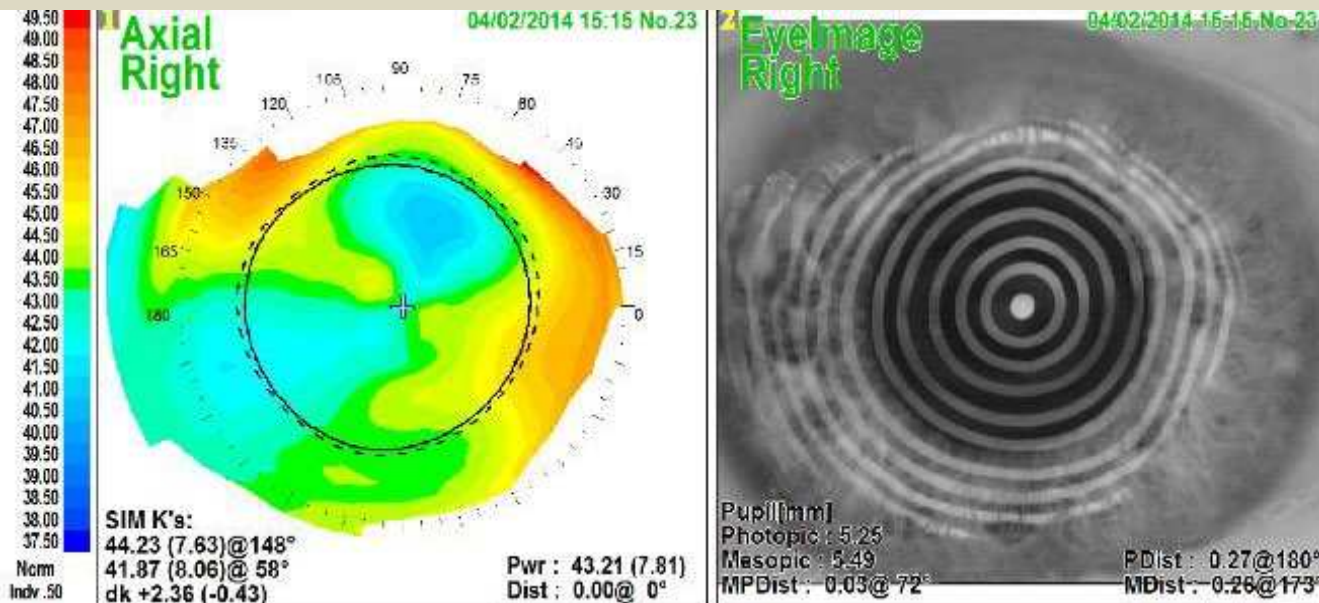
## RIGHT EYE

5 yrs after DALK (10mm diameter)

4 yrs after cat extraction with Alcon SN6AT5 IOL

Uncorrected Distance VA remains 20/20- plano !

Demonstrates EXCELLENT long-term refractive stability!





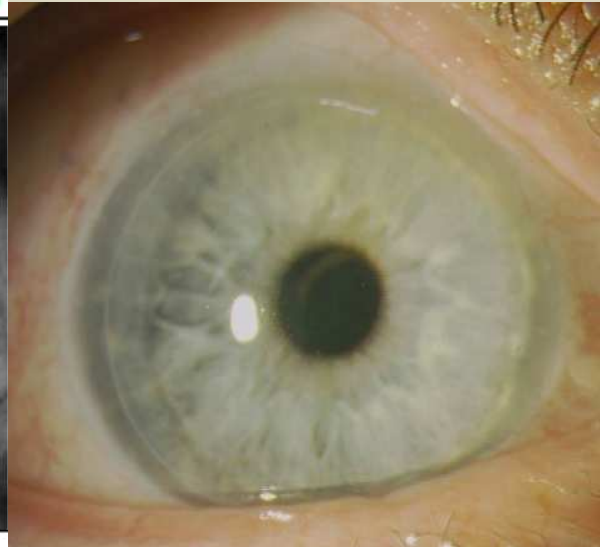
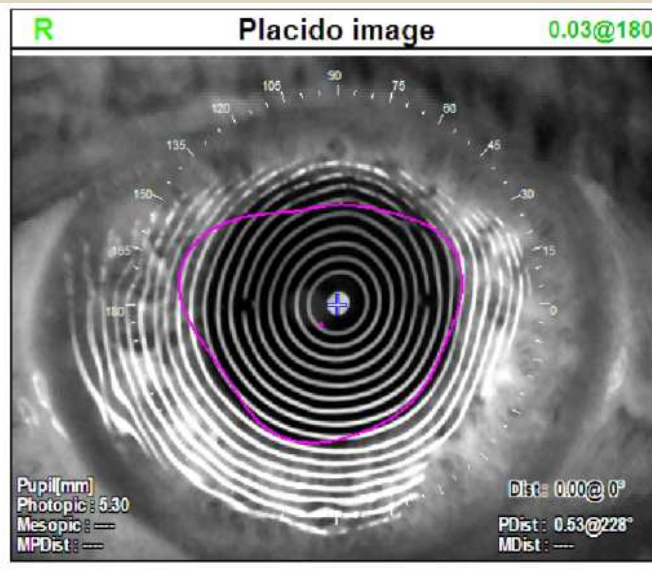
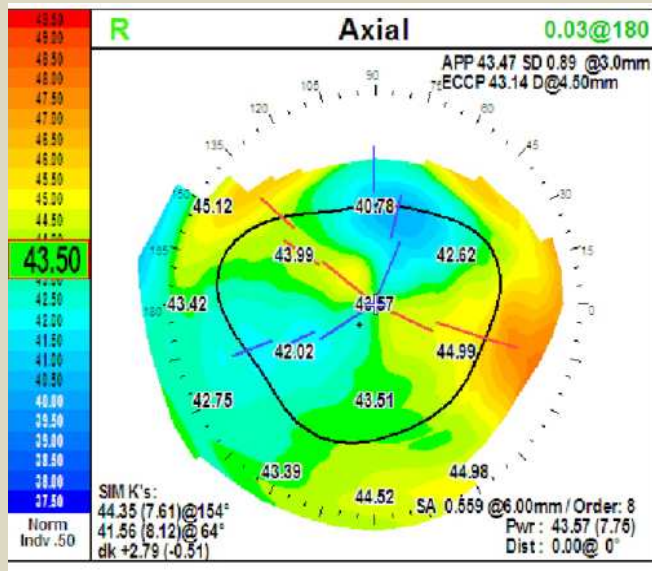
# RIGHT EYE

8 yrs after DALK (10mm diameter)

7 yrs after cat extraction with Alcon SN6AT5 IOL

Uncorrected Distance VA remains 20/20- plano !

Demonstrates EXCELLENT long-term refractive stability!



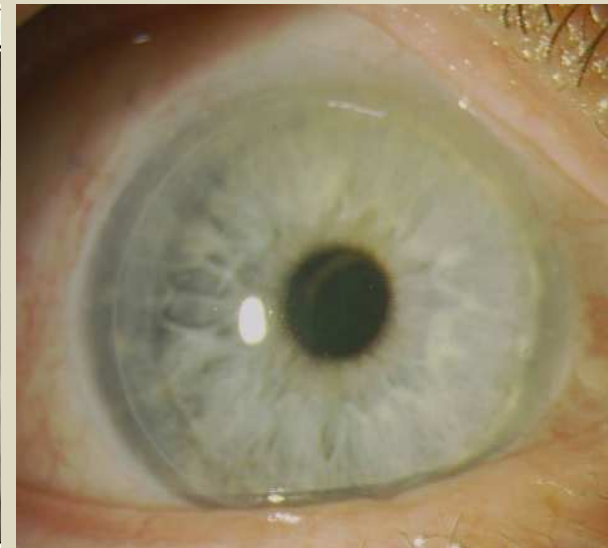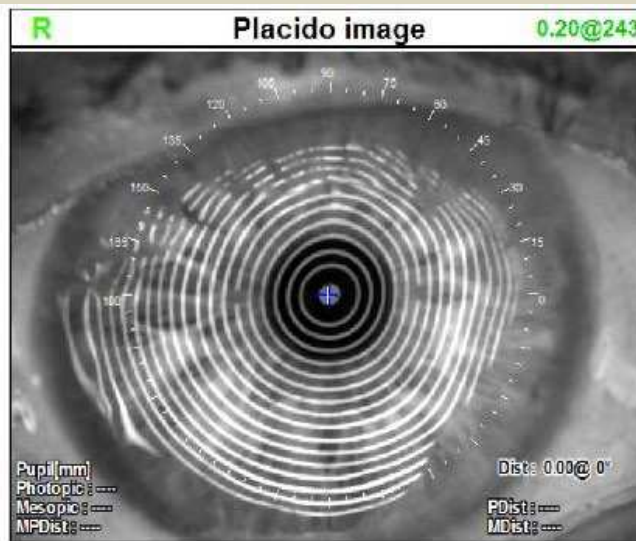
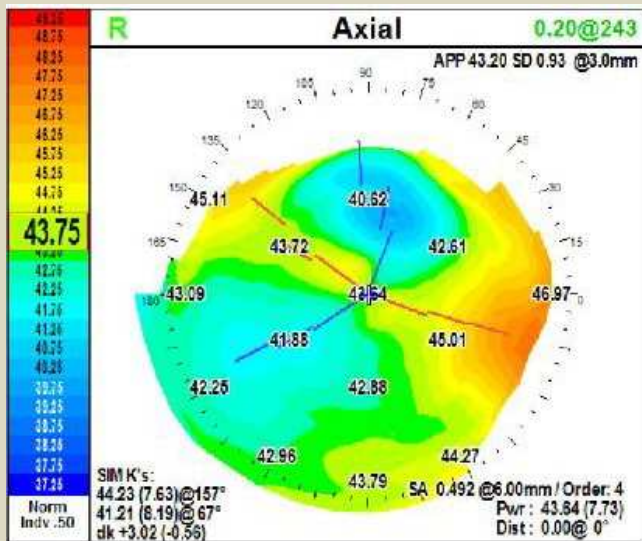
# RIGHT EYE

14 yrs after DALK (10mm diameter)

13 yrs after cat extraction with Alcon SN6AT5 IOL

Uncorrected Distance VA remains 20/20- plano !

Demonstrates EXCELLENT long-term refractive stability!

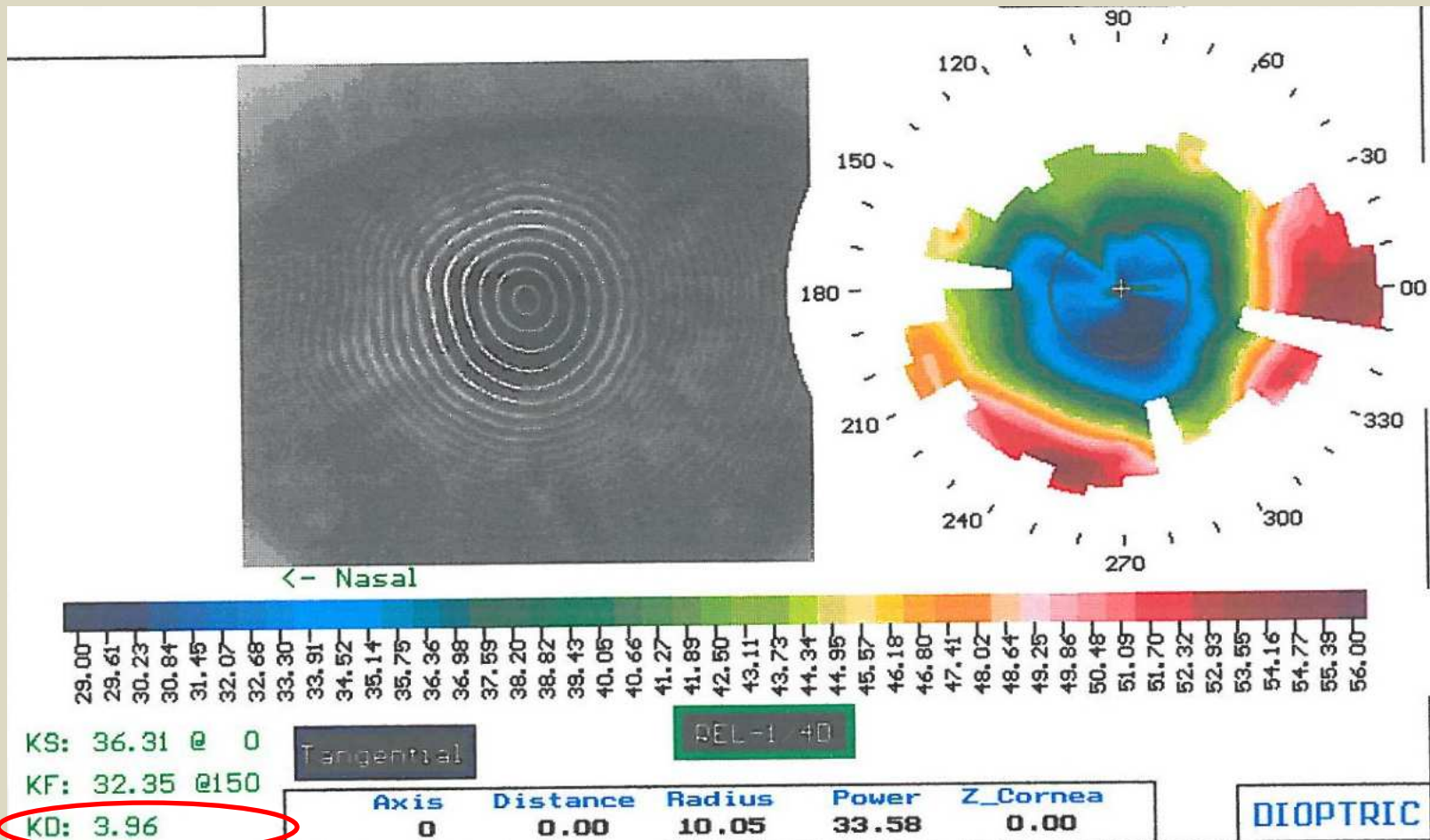


# Left Eye

64 year old with cataract and RK-induced cornea ectasia

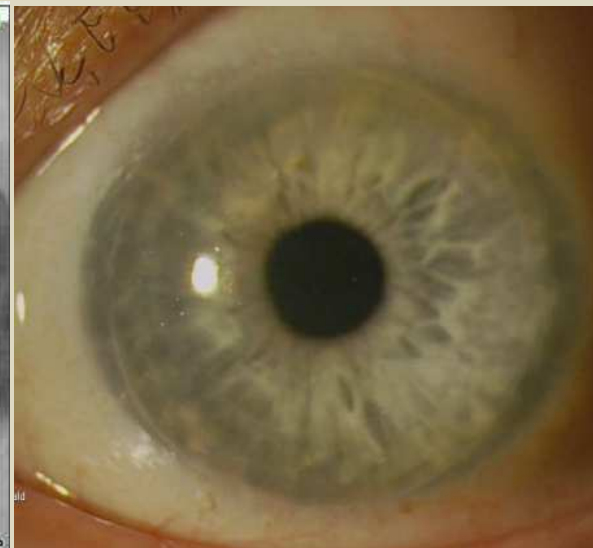
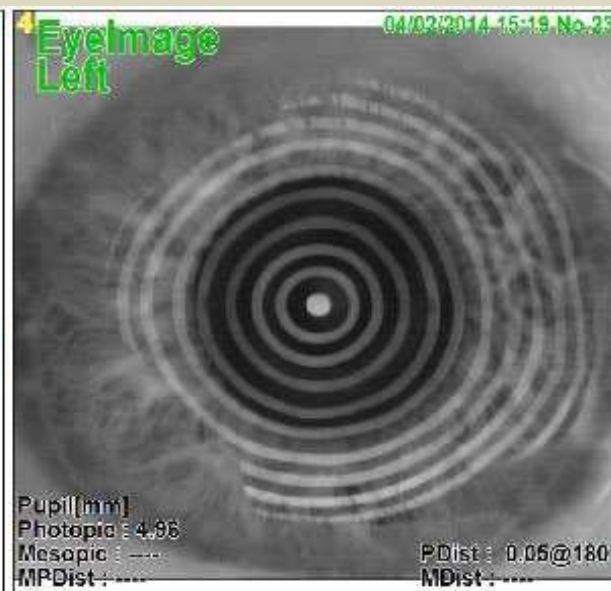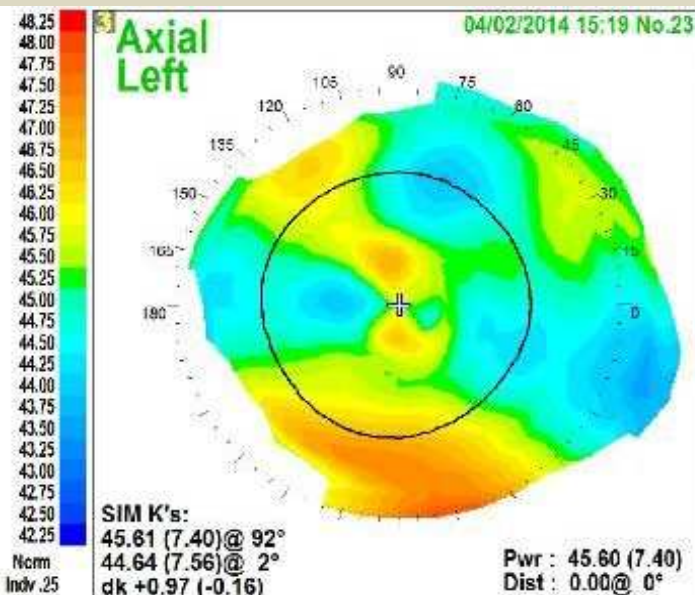
Progressive hyperopia, irregular astigmatism

OS: +4.50 + 2.25 x 25 20/30 pre-op



# LEFT EYE

3 yrs after DALK (10mm diameter)  
2 yrs after cat extraction with Alcon SN6AT4 IOL  
Uncorrected Distance VA remains 20/20- plano !  
Demonstrates EXCELLENT long-term refractive stability!



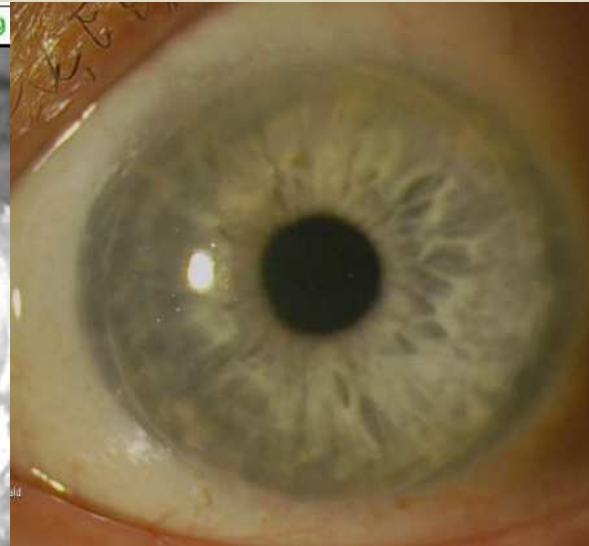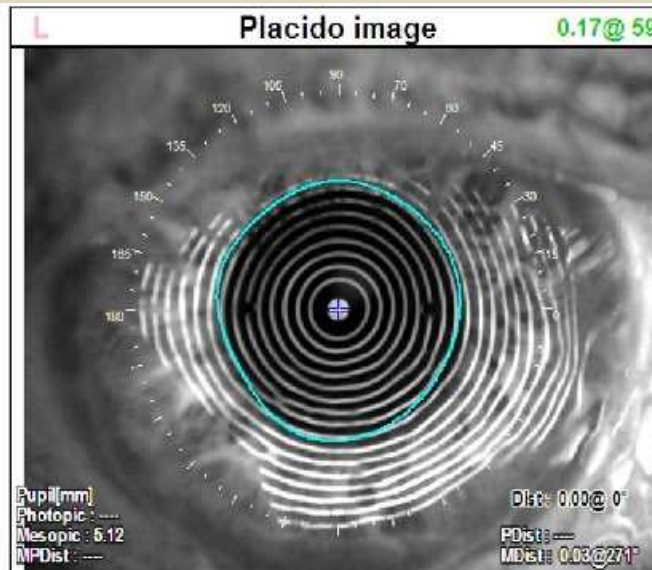
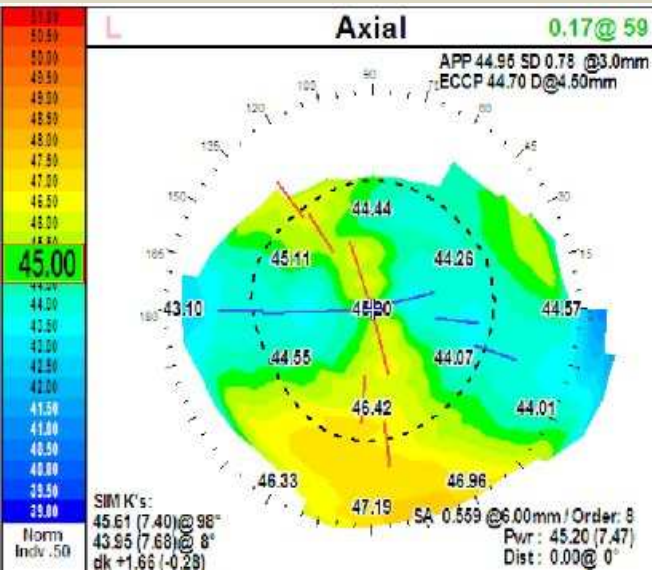
# LEFT EYE

6 yrs after DALK (10mm diameter)

5 yrs after cat extraction with Alcon SN6AT4 IOL

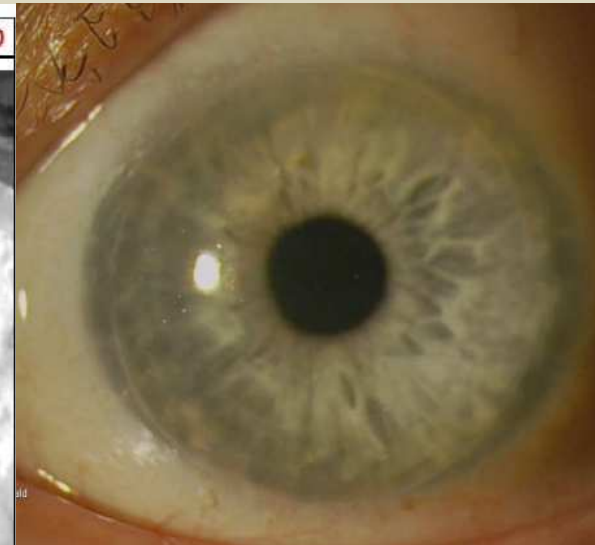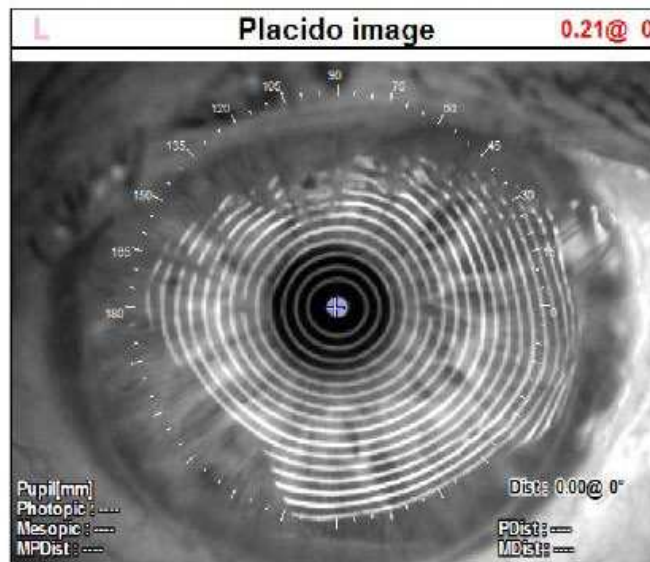
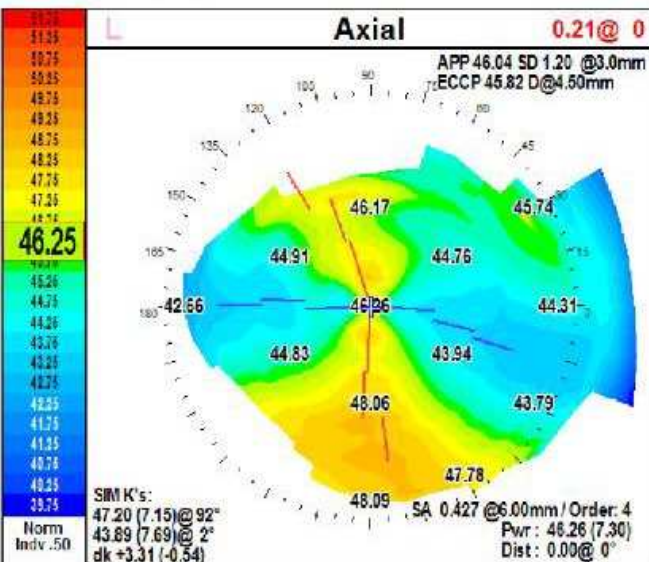
Uncorrected Distance VA remains 20/20- plano !

Demonstrates EXCELLENT long-term refractive stability!



# LEFT EYE

12 yrs after DALK (10mm diameter)  
11 yrs after cat extraction with Alcon SN6AT4 IOL  
Uncorrected Distance VA 20/30-  
Demonstrates EXCELLENT long-term refractive stability!



## Case # 1: Observations

large diameter DALK OU for bilateral RK ectasia  
with subsequent suture-out cataract extraction toric IOL OU

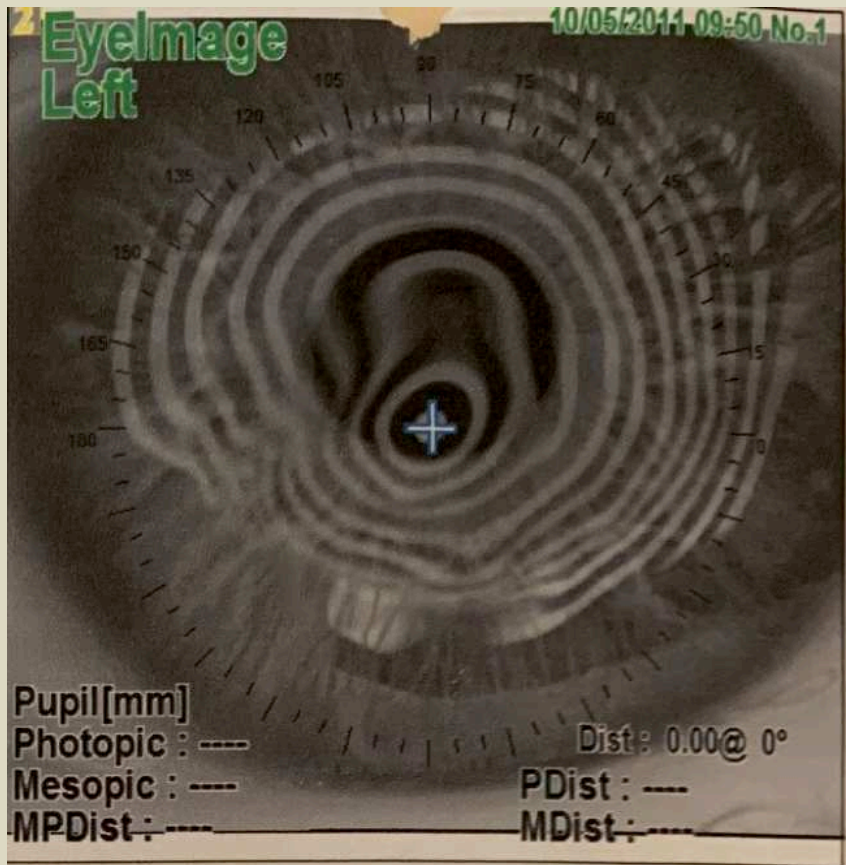
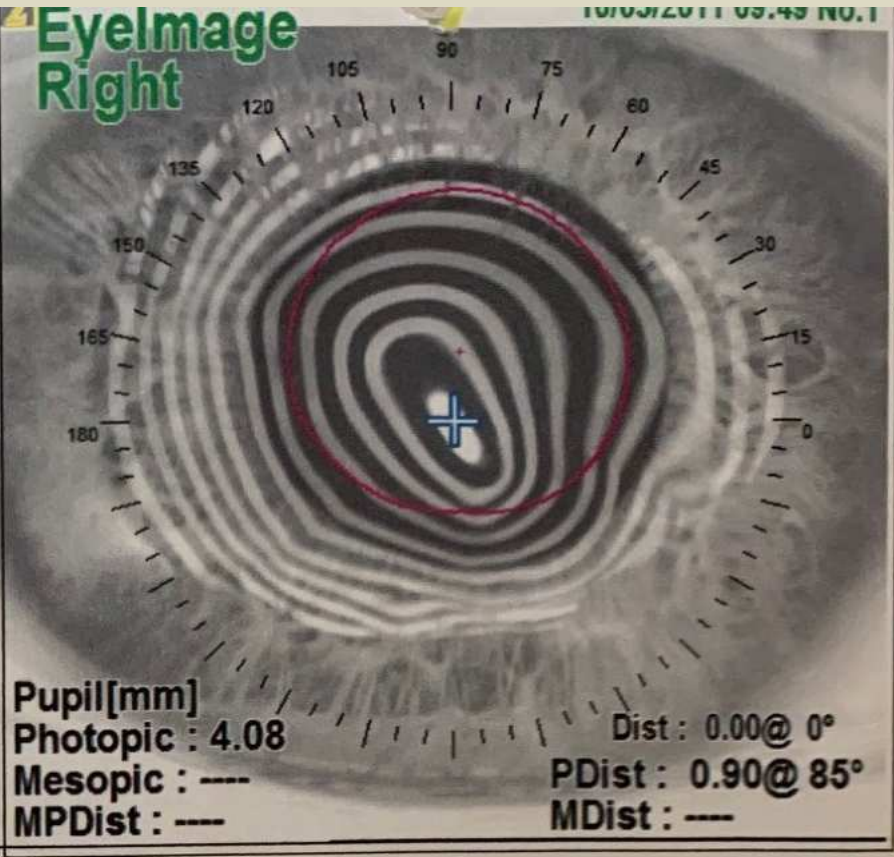
- Fully Restorative OU, exceeding patient expectations.
- Provided excellent uncorrected Visual Acuity OU stable over a decade.

Is DALK Adjustable after the suture is removed?



# Case 2: Bilateral severe RK ectasia 64yo

OD 20/150                      OS 20/200



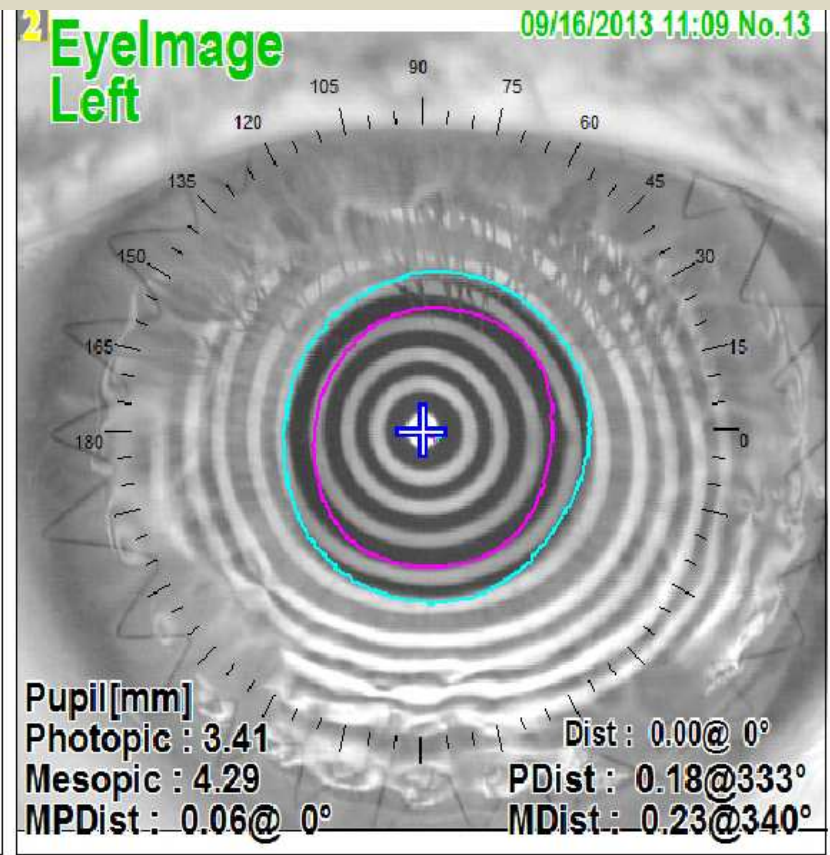
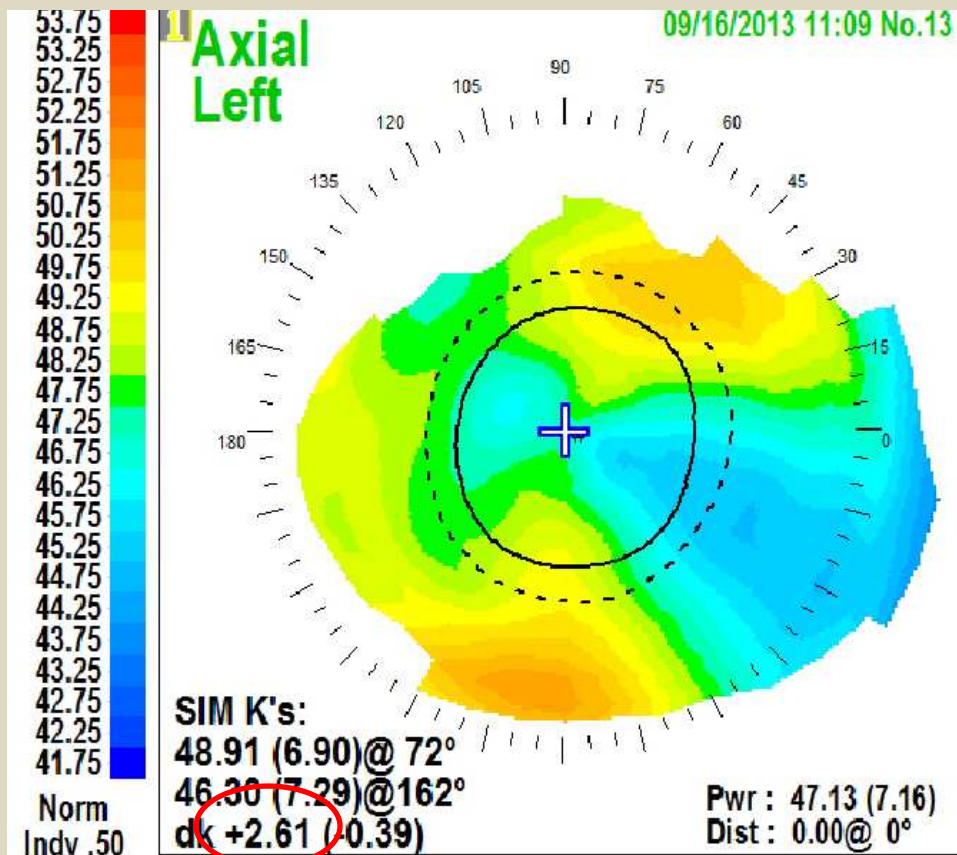
# Case 2: Left eye: RK ectasia

4/2012 DALK 9.5mm

5/2012 -8.0 + 2.25 x 70 20/25

(Early optical rehabilitation – fit with toric soft contact lens)

9/2013 topography below

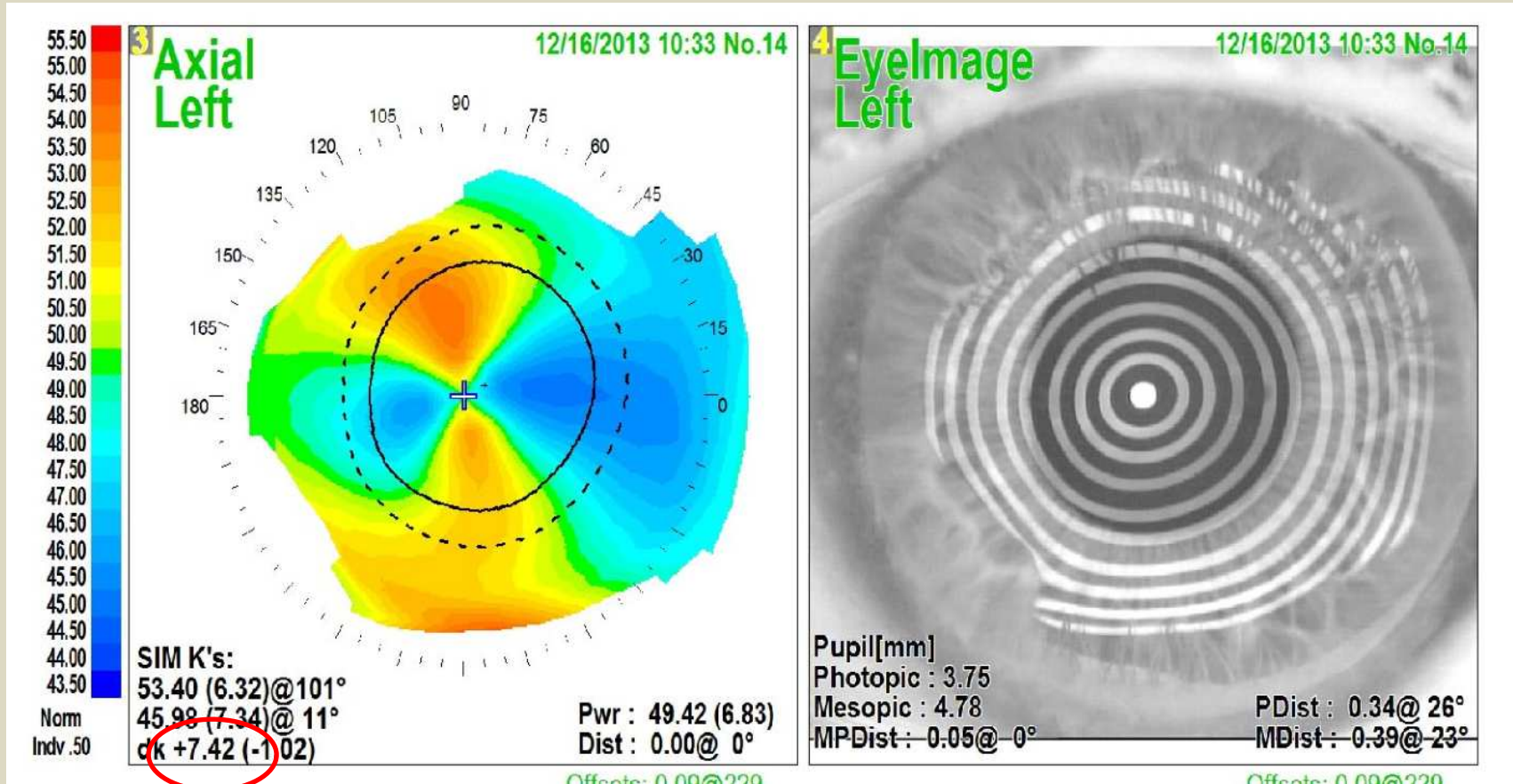


# CASE 2: Left Eye: RK ectasia

4/2012 DALK 9.5mm

9/2013 running suture removal

12/2013 note increased cylinder (+7.42D)

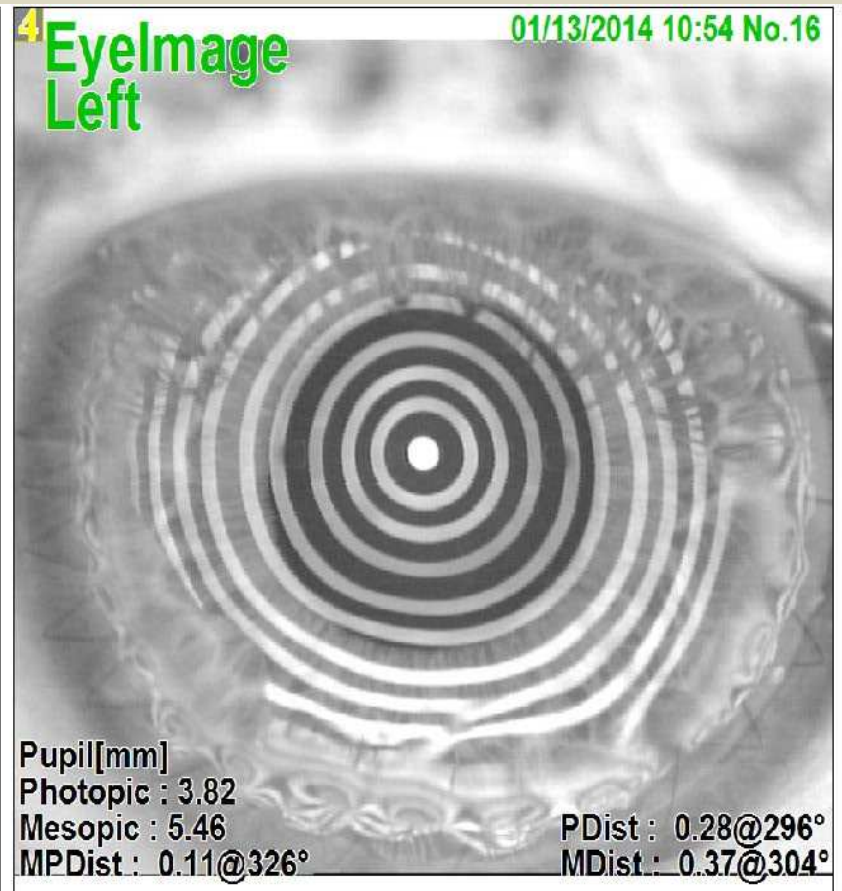
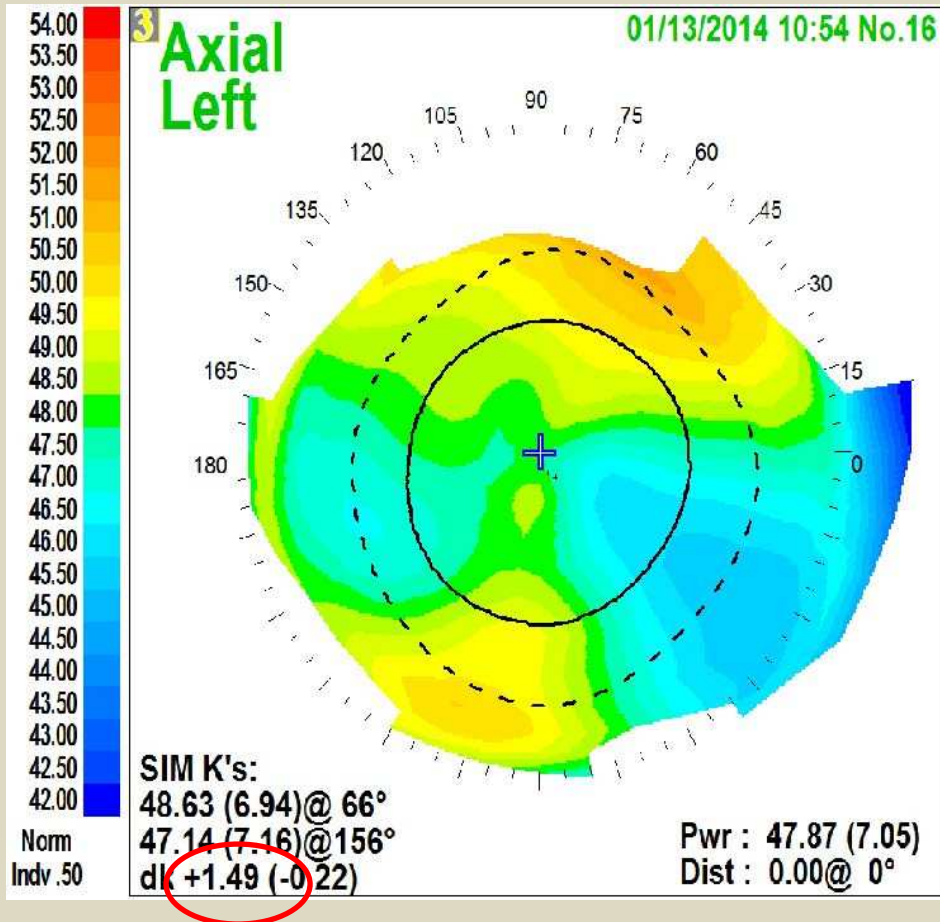


# Case 2: Left eye: RK ectasia

4/2012 DALK 9.5mm-

12/2013 replaced running suture fit with soft contact lens

1/2014 cylinder dramatically reduced (+1.49D)



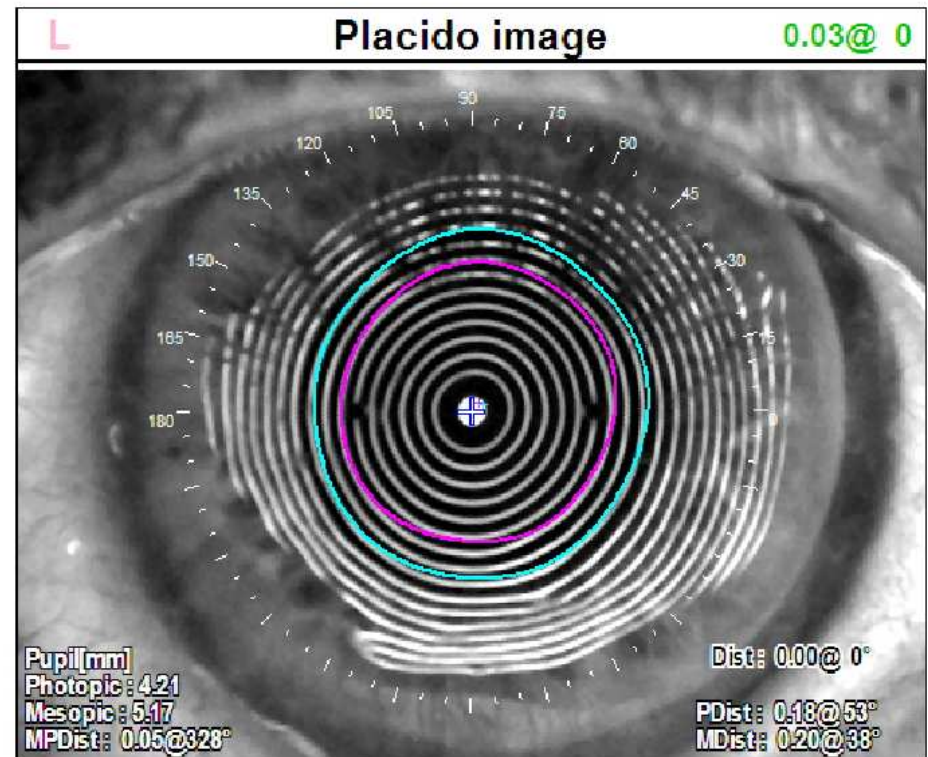
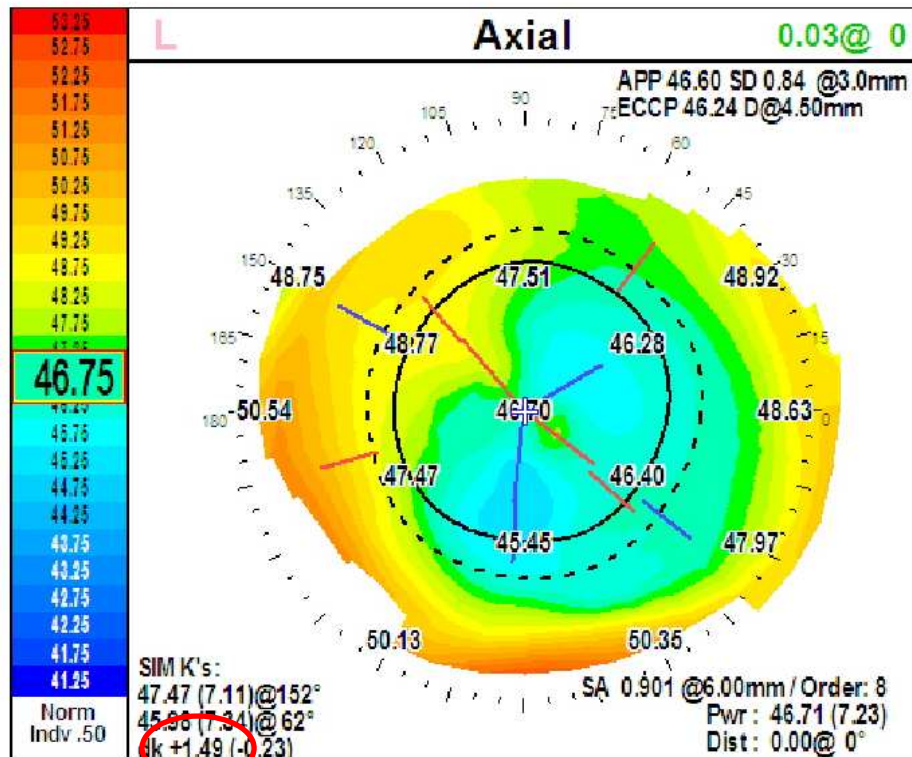
# Case 2: Left eye: RK ectasia

4/2012 DALK 9.5mm

12/2013 replaced running suture fit with soft contact lens

6/2019 5 1/2 yrs later...removed running suture

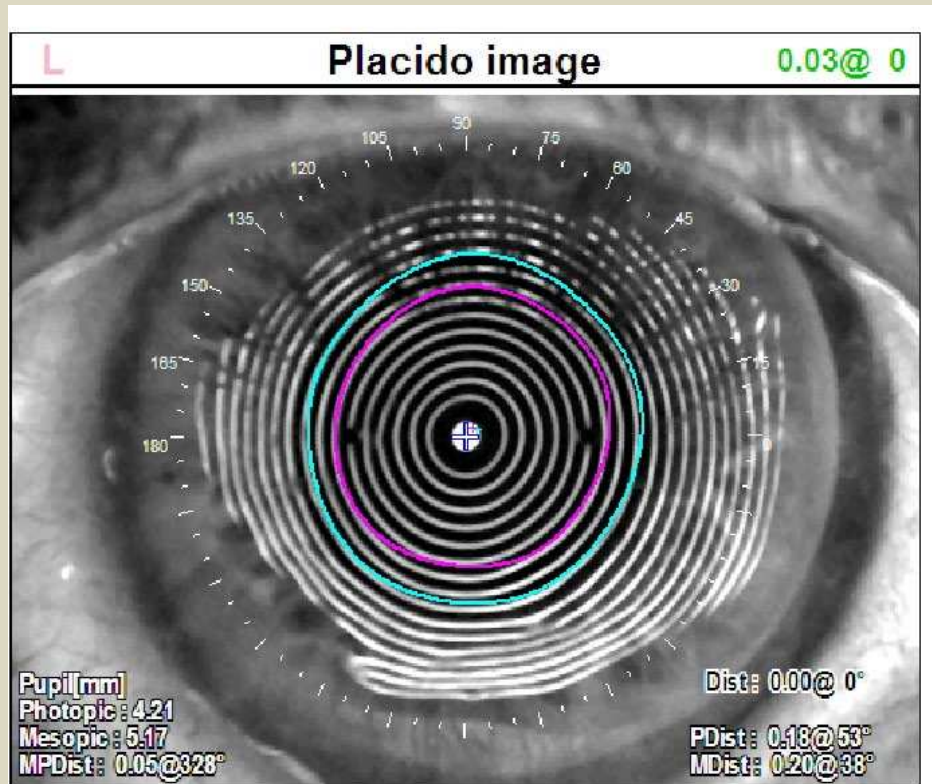
7/2019 -9.25+2.25x20 20/40 (cataract) astig remains 1.49D!



# Left eye: Great result!!

## 8/2019 Cataract Ext with low power toric IOL

- UCVA 20/30
- $-0.75 + 0.75 \times 50$  20/20



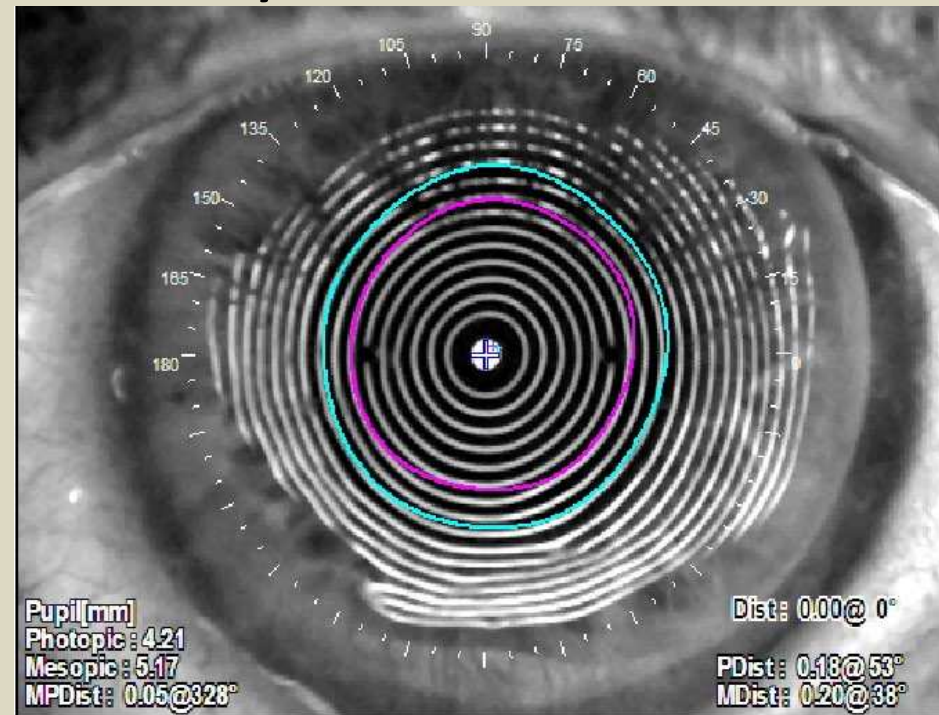
# Left eye: 9 yrs after DALK, Great result!!

## 8/2019 Cataract Ext with low power toric IOL

- UCVA 20/30
- $-0.75 + 0.75 \times 50$  20/20
- Pre-op



## 9 yrs after DALK!

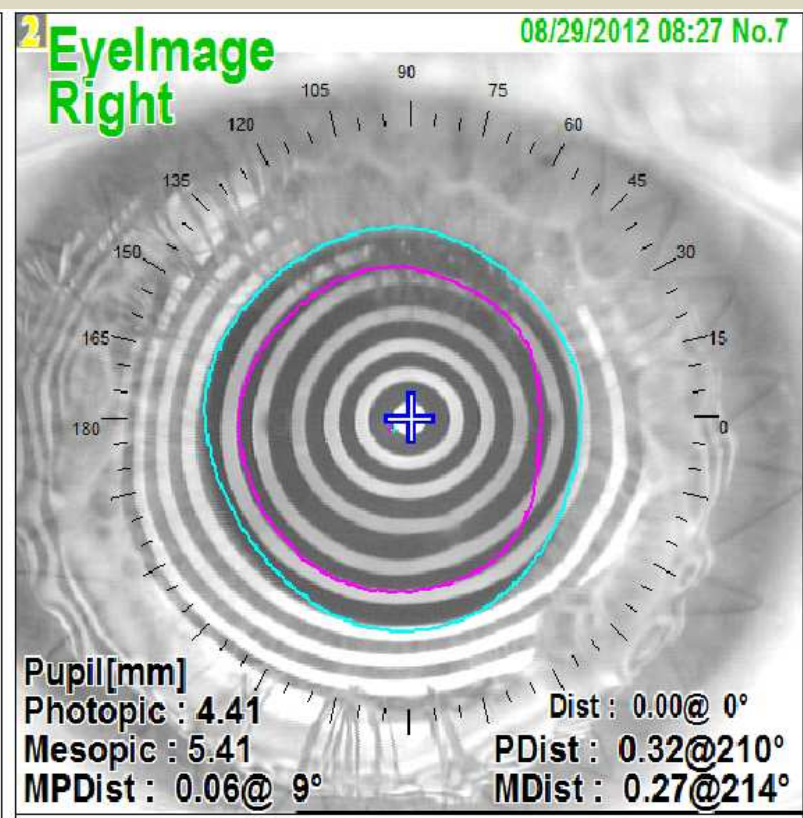
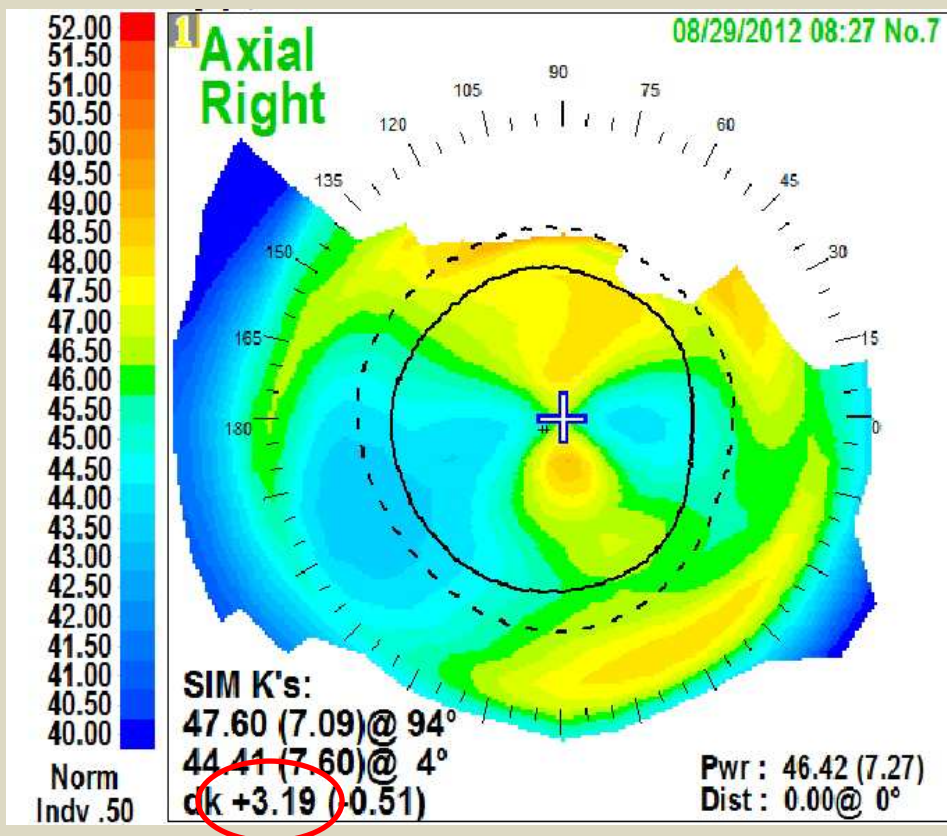


# CASE 2: Right eye: RK ectasia

7/2012 DALK 10.0mm

8/2012 -7.75+3.0x93 20/30

(Early optical rehabilitation – fit with toric soft CL)

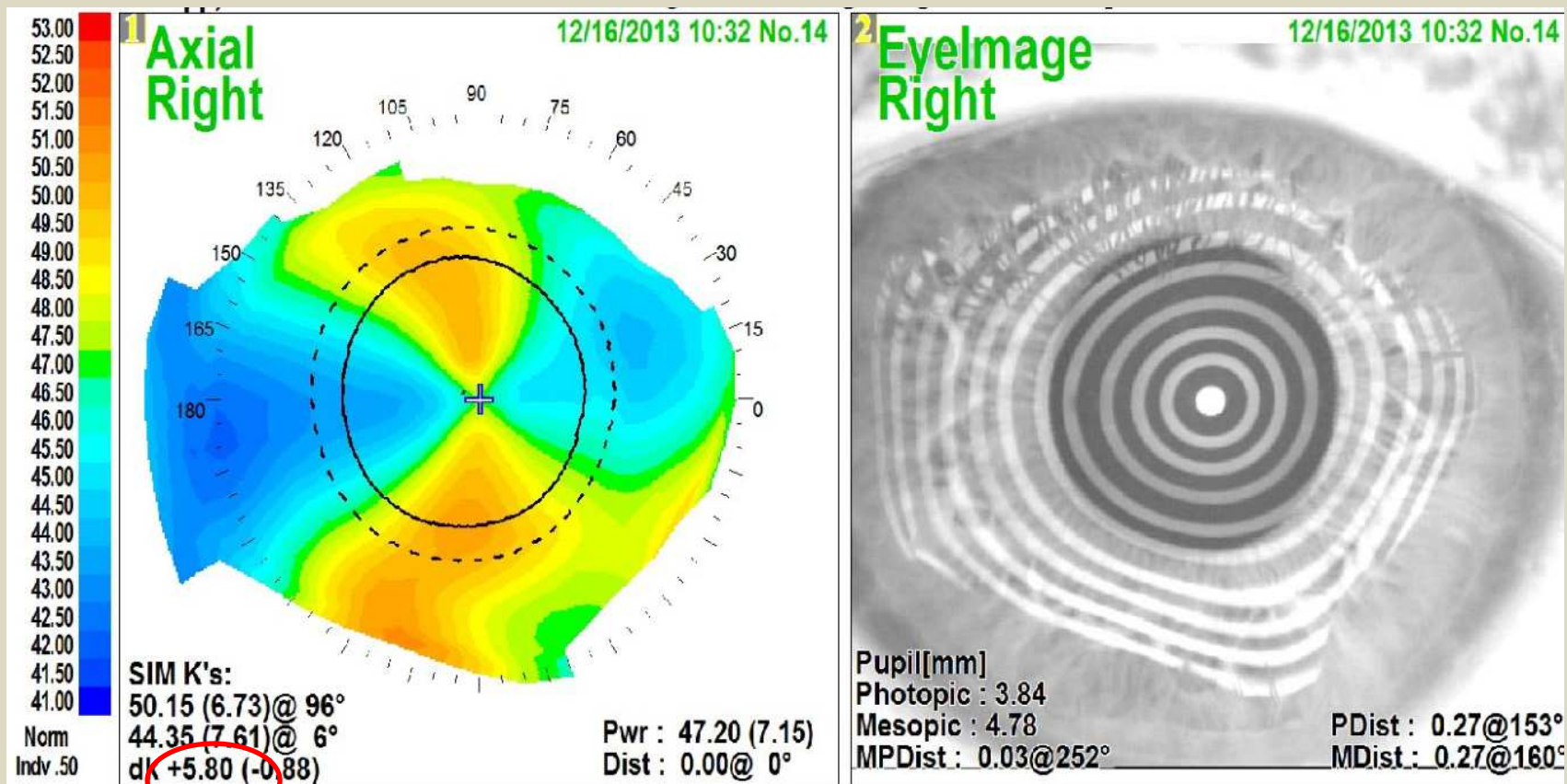




# CASE 2: Right eye – RK ectasia

7/17/12 DALK 10.0mm

7/2013 removed running suture - high astig (+5.8D)



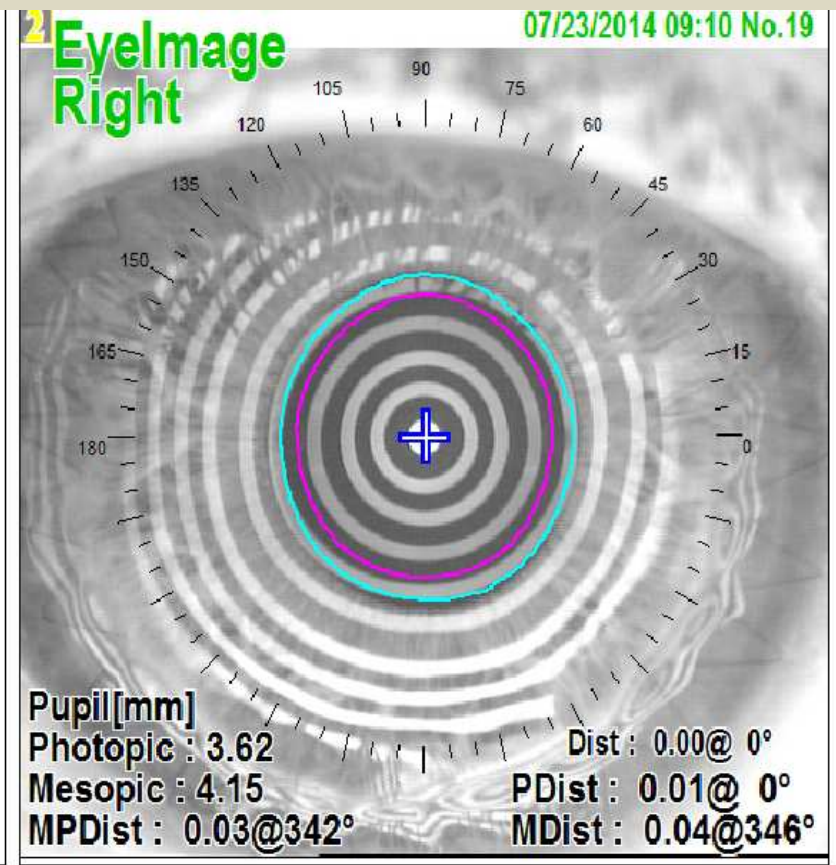
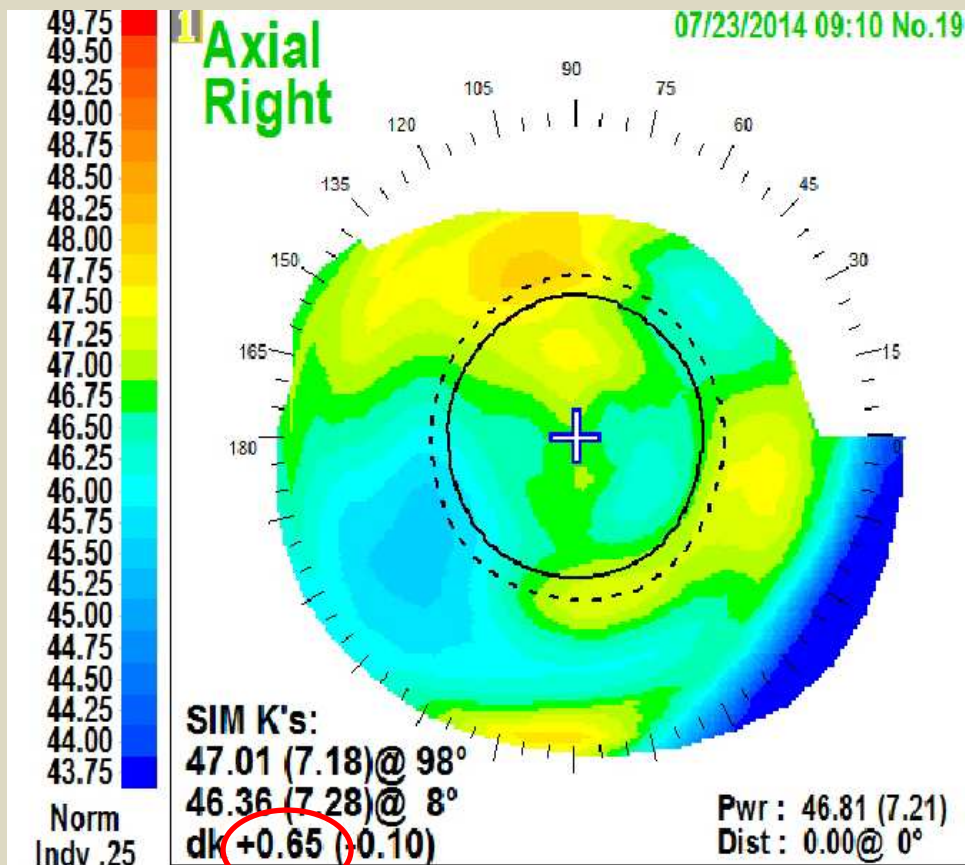
# CASE 2: Right eye: RK Ectasia

7/17/12 DALK 10.0mm

7/2013 removed running suture - high astigmatism

3/2014 small wedge resection, replace running suture

7/2014 -10+1.75x157 20/40 fit with soft toric contact lens



# CASE 2: Right eye: RK Ectasia

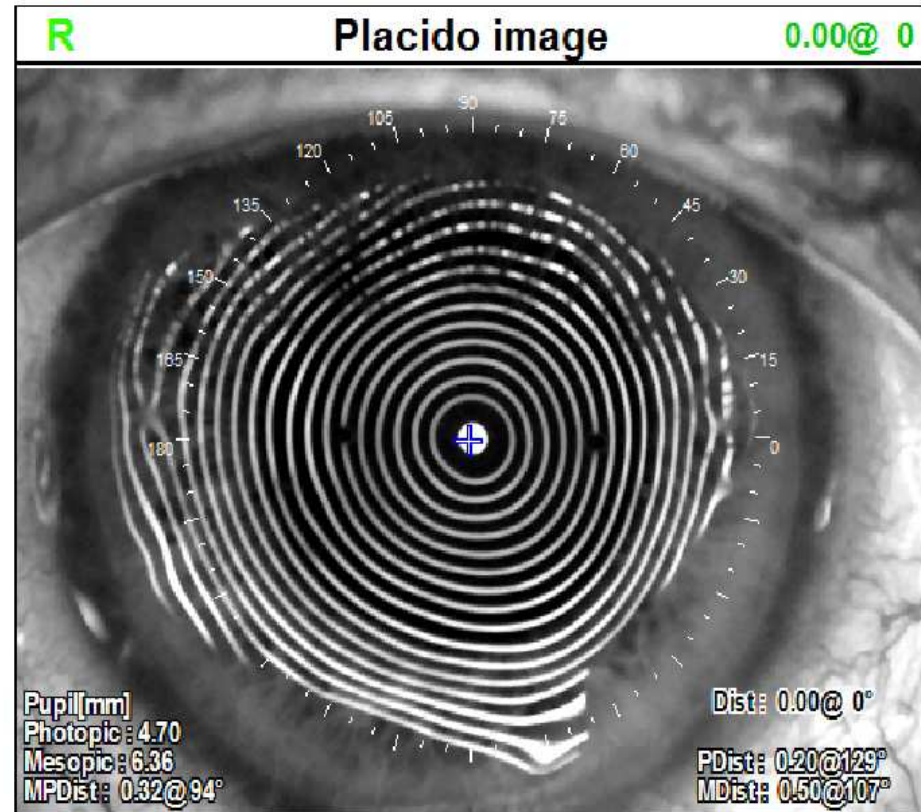
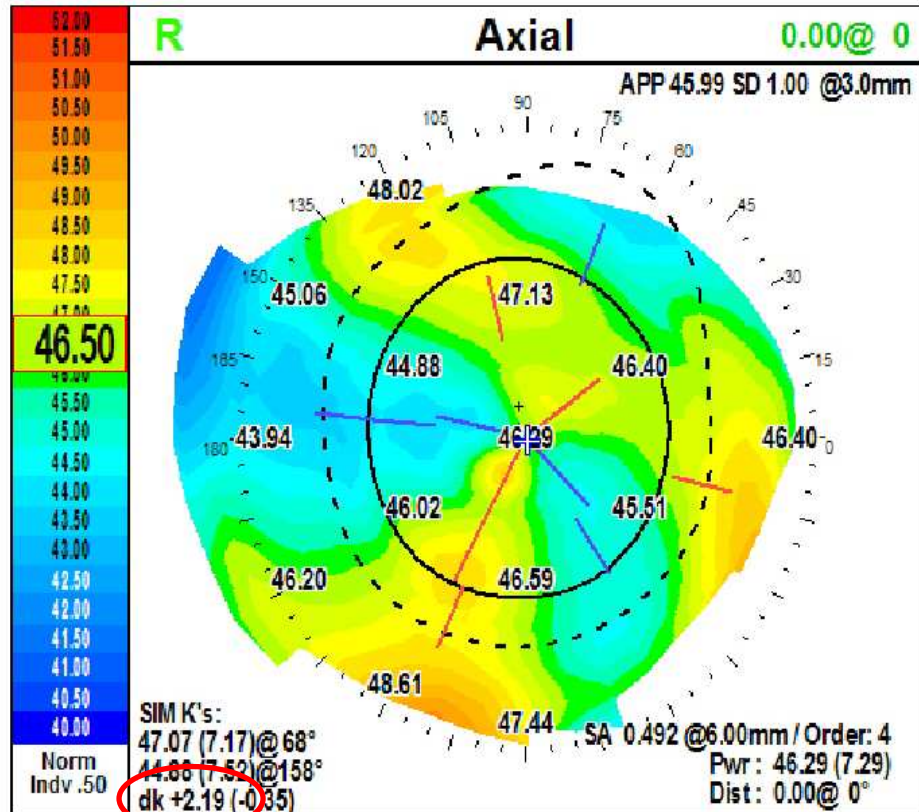
7/17/12 DALK 10.0mm

7/2013 removed running suture - high astigmatism

3/2014 wedge resection, replace running suture

9/2019 removed running suture (5yrs later)

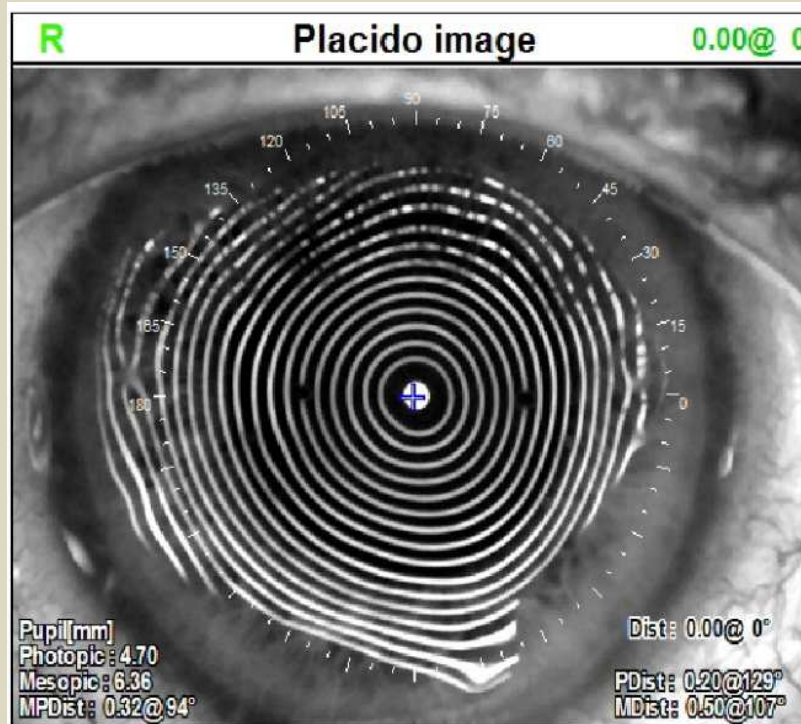
10/2019 -11.5+1.0x70 20/40 (cataract) note: lower astig +2.19D!



# Right Eye: Happy endings!!

10/2019 Cataract Ext with low power toric IOL OS

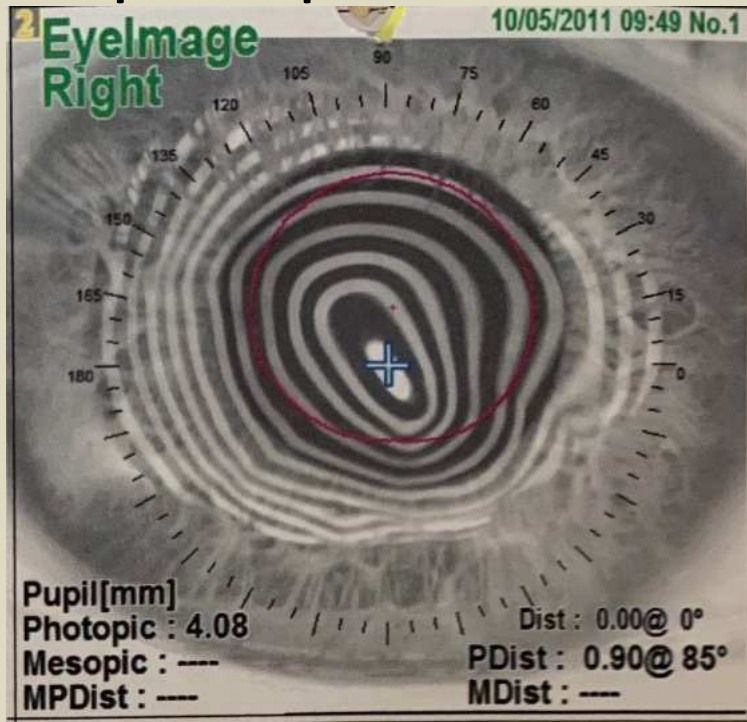- UCVA 20/30
- -0.50+ 0.75 x 20 20/30



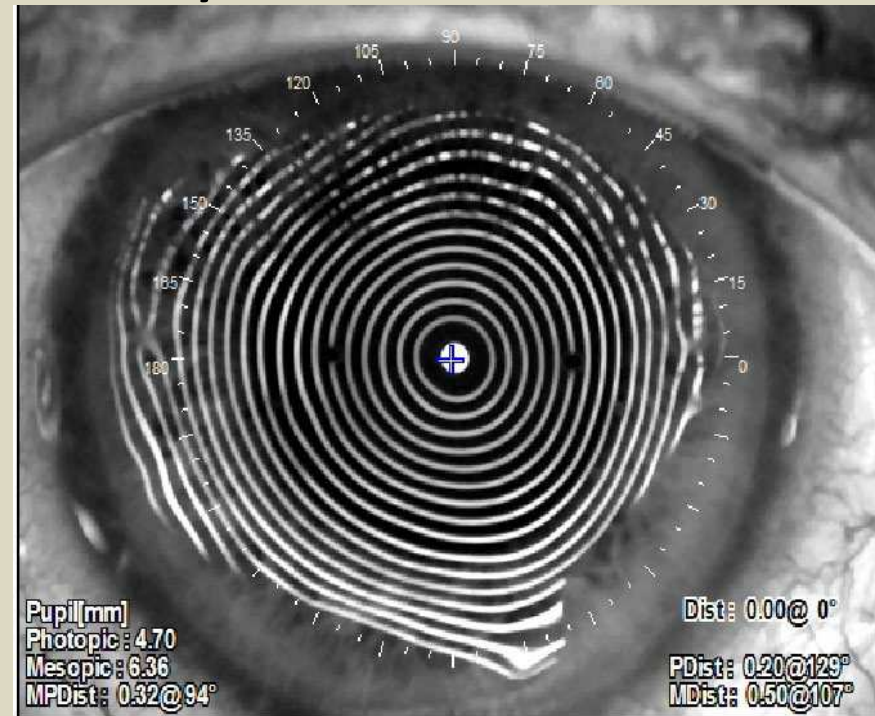
# RIGHT eye 9 years after DALK Great result!!

## 10/2019 Cataract Ext with low power toric IOL OS

- UCVA 20/30
- -0.50+ 0.75 x 20 20/30
- pre-op



## 9 yrs after DALK!



## Case 2: Observations: 9 years after DALK OU for severe RK ectasia and subsequent delayed cataract extraction with IOL:

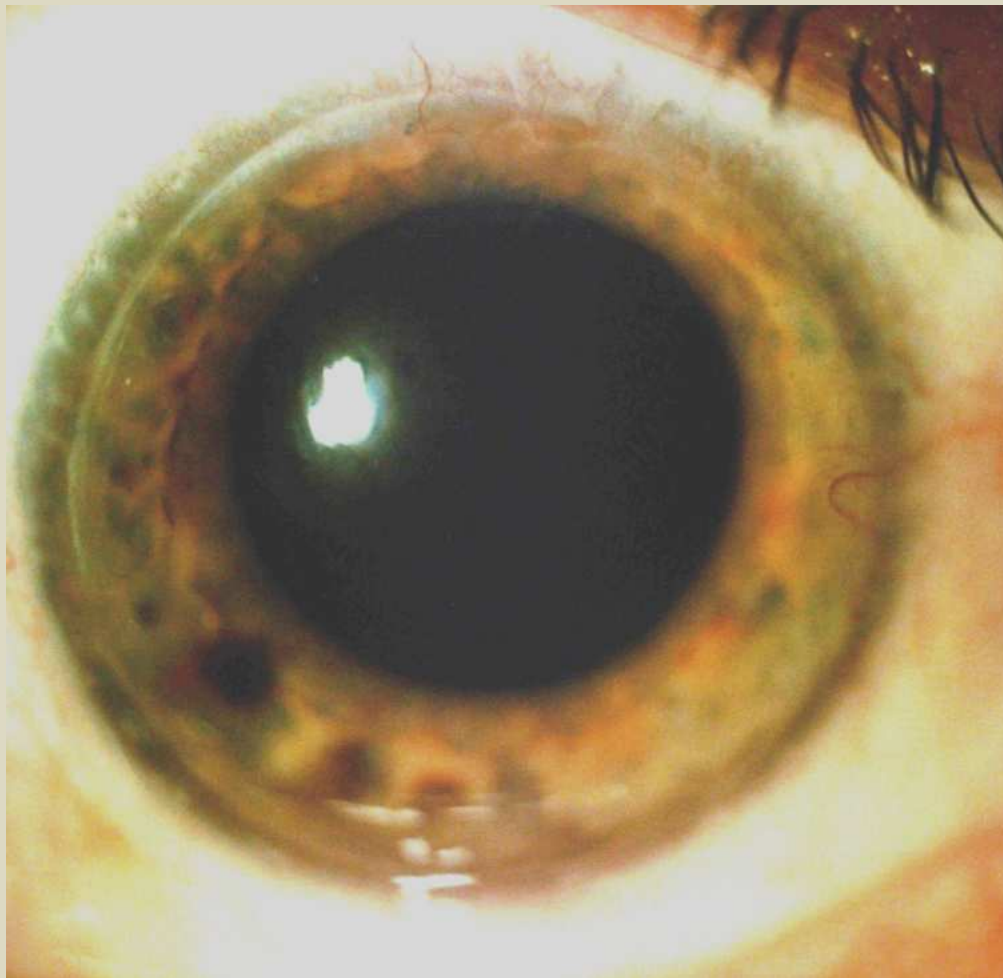
- Both eyes achieved early optical rehabilitation one month after initial DALK
- At one year after DALK, running suture was removed resulting in excessive regular astigmatism. This same experience occurred in each eye. Running suture replacement with adjustment under intraoperative keratometer to achieve approximate sphericity was required OU to neutralize excessive regular astigmatism. Suture was left in place additional 5 years in each eye optically rehabilitated with soft contact lenses during this time.
- After running suture removal the second time OU, years later, minimal Astig/cylinder drift occurred in either eye and cataract extraction with low magnitude toric IOL was used for final “optical rescue” of each eye.
- The result of this and other similar cases, suggests use of a running suture in large diameter DALK can be used to “train” the cornea graft to maintain approximate sphericity not just in the initial post-op period but long term if required. This has NOT been my experience in large diameter PK where the cornea shape typically dramatically relaxes after running suture removal many years later. This is best explained by poor coaptation in PK grafts compared to dramatically better coaptation in DALK grafts!

Case #3: OD 49yo

1989 RK: Bogata, Columbia

2012 RK severe ectasia DALK 10mm Richard Erdey, MD

2016 Cataract Ext with Toric IOL UCVA 20/30



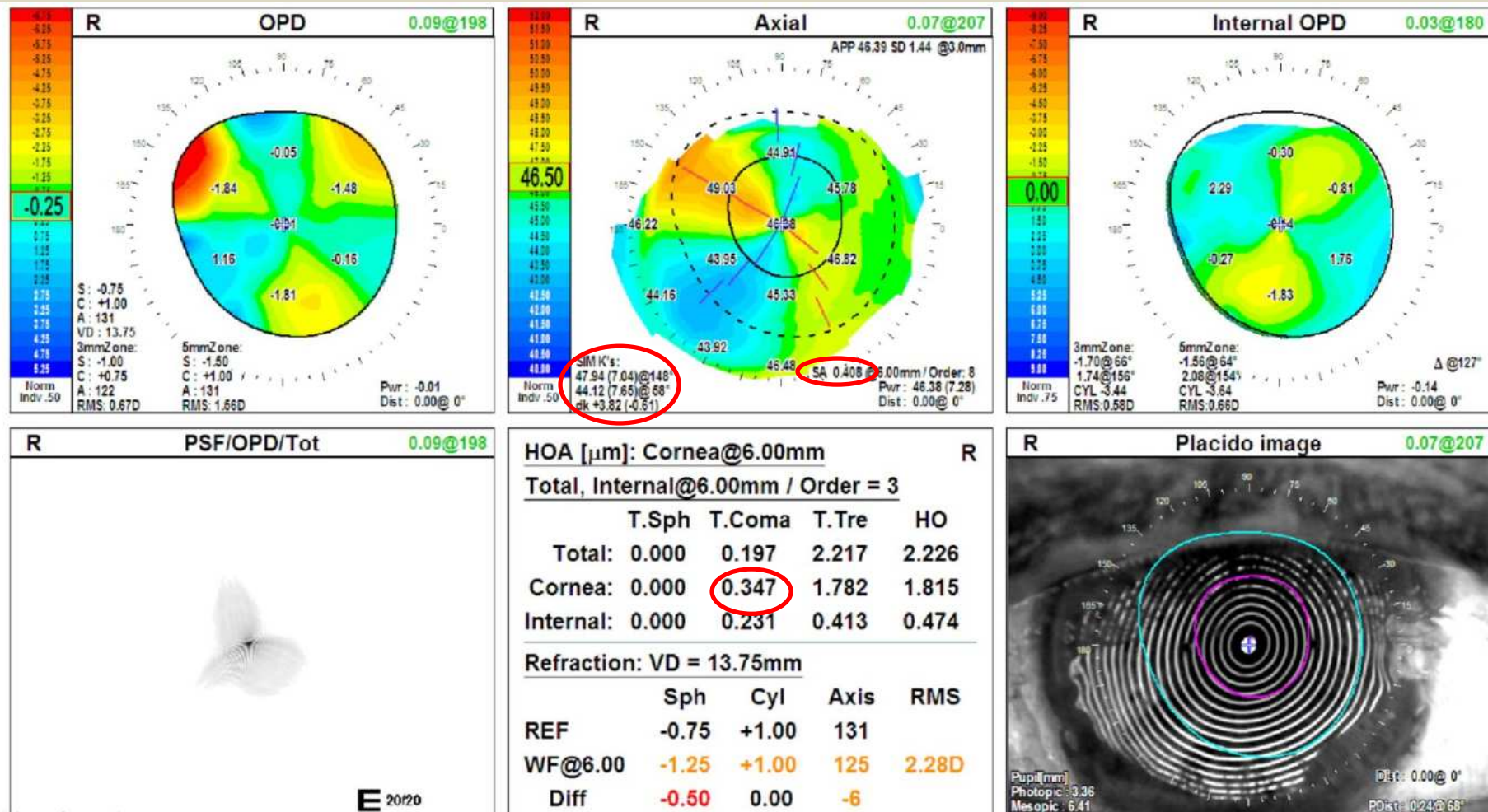
# Case #3: OD

1989 RK: Bogata, Columbia

2012 RK ectasia DALK 10mm Richard Erdey, MD

2016 Cataract Ext with Toric IOL UCVA 20/30

2018 Topo below UCVA 20/30





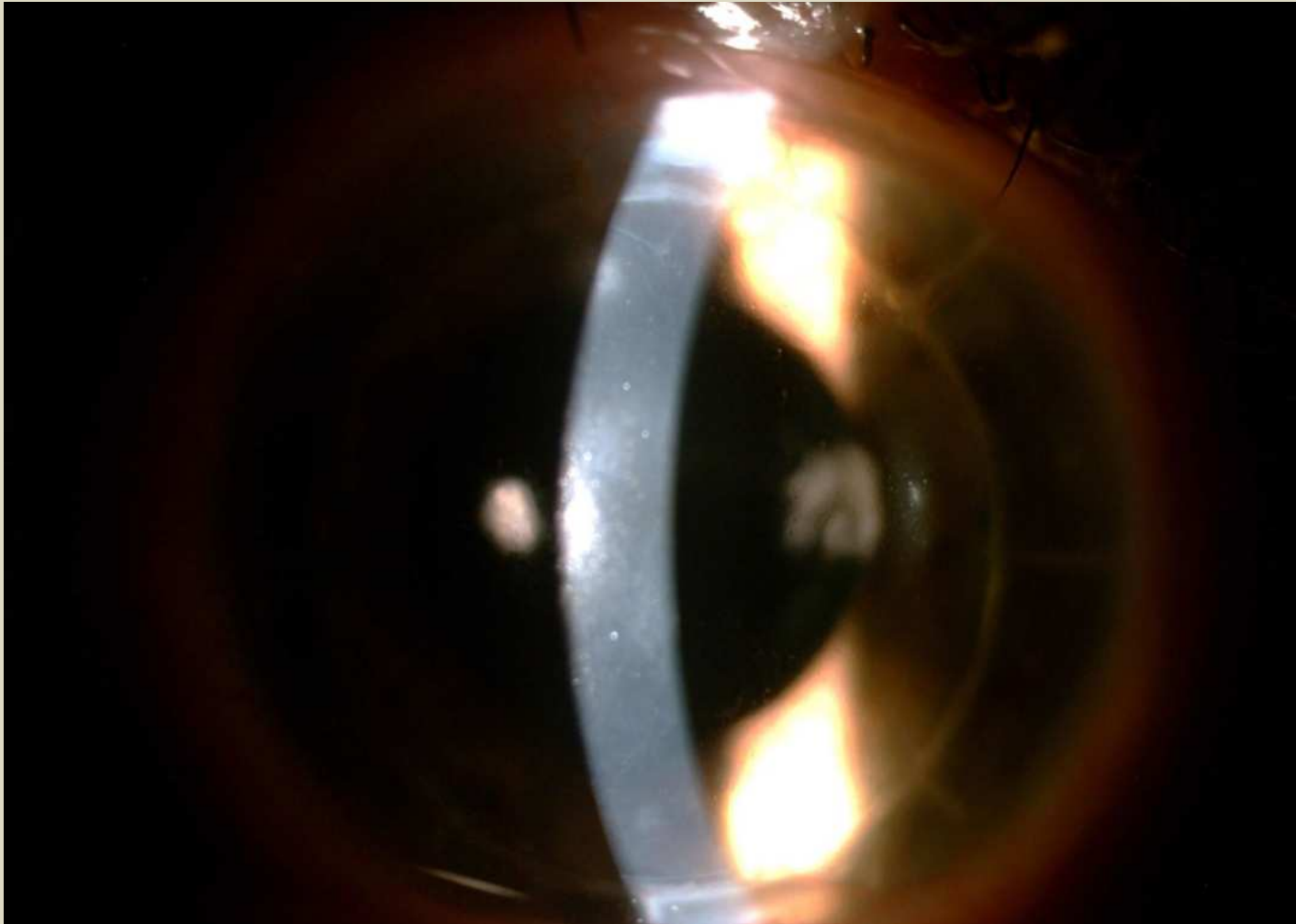
Case #3 OS

1989 RK Bogata, Columbia

1991 RK Ectasia, Penetrating Keratoplasty (PK) 8.0mm Jose Barraquer, MD

Interim: worn GPHCL : -12.0+2.5x65

7/24/18 Cataract Extraction with Toric IOL UCVA 20/30



# Case #3 OS

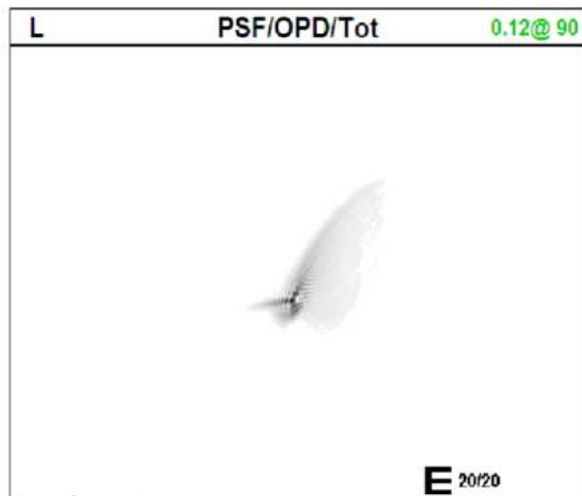
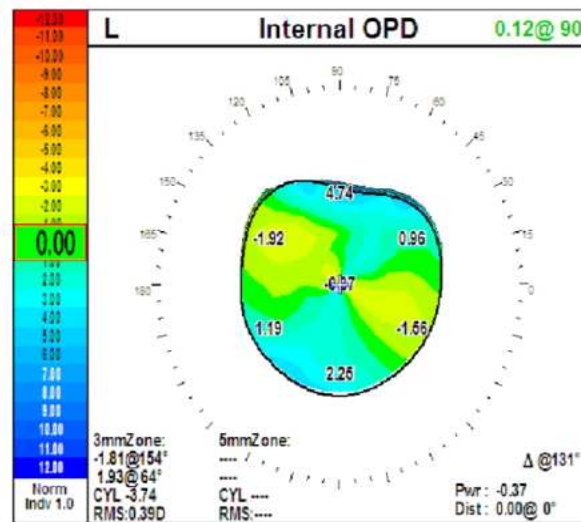
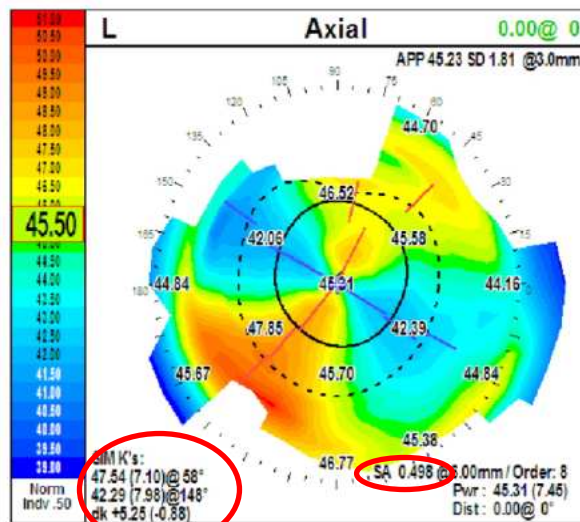
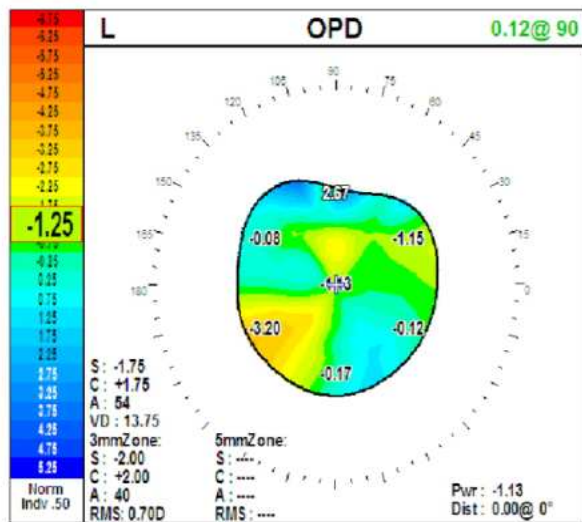
1989 RK Bogata, Columbia

1991 RK Ectasia, PK 8.0mm Jose Barraquer, MD

Interim: worn GPHCL : -12.0+2.5x65

6/2018 Cataract Extraction with Toric IOL UCVA 20/30 Richard Erdey, MD

12/2018 topography below UCVA 20/30



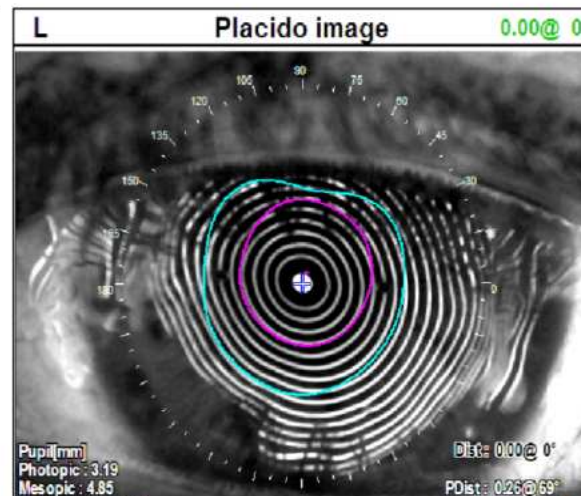
HOA [ $\mu$ m]: Cornea@6.00mm

Total, Internal@5.40mm / Order = 3

	T.Sph	T.Coma	T.Tre	HO
Total:	0.000	0.268	0.912	0.951
Cornea:	0.000	0.526	1.274	1.378
Internal:	0.000	0.122	0.058	0.136

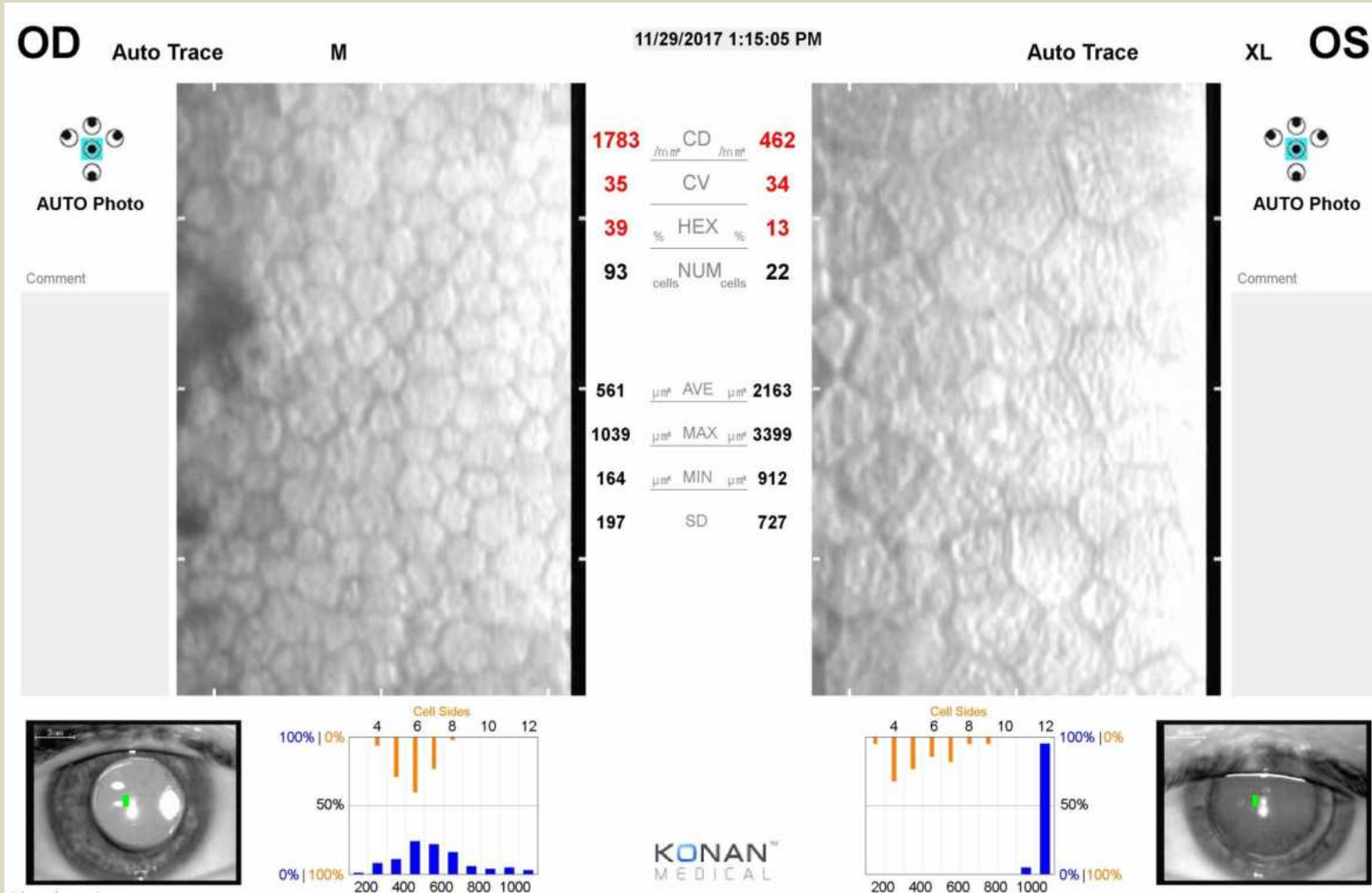
Refraction: VD = 13.75mm

	Sph	Cyl	Axis	RMS
REF	-1.75	+1.75	54	
WF@4.85	-1.75	+2.25	43	0.86D
Diff	0.00	+0.50	-11	



# 2017 ENDOTHELIAL CELL COUNT

2012 OD: DALK                      1991 OS: PKP



### Case #3: Observations:

RK ectasia OU

OD: DALK large diameter, with suture out cataract extraction toric IOL

OS: PKP with delayed cataract extraction toric IOL

- DALK (large diameter) OD: 7 yrs post DALK. has less astigmatism and better corneal HOA's than other (OS) eye which had a PK. This correlates with this patients subjective observations (prefers OD>OS). Recipient endothelial cells are PRESERVED, cell count decay will NOT occur. This graft is expected to last a lifetime.
- PK OS demonstrates higher astigmatism and HOA's with very low endothelial counts, as expected, 28yrs later. The graft will decompensate in the near future and DMEK/DSEK will be necessary to "refresh" the insufficient endothelial cell counts. We can anticipate a hyperopic shift afterwards. This future intervention will NOT be required in the other (OD) DALK eye .

Case 4 63 yo RK ectasia OU, presents in 12/2019 “very unhappy” “no visual improvement – very poor vision quality “even worse at night” “cannot drive” and persistent diurnal fluctuation OU despite crosslinking (OS) 2013 and cataract surgery (OU) 2018

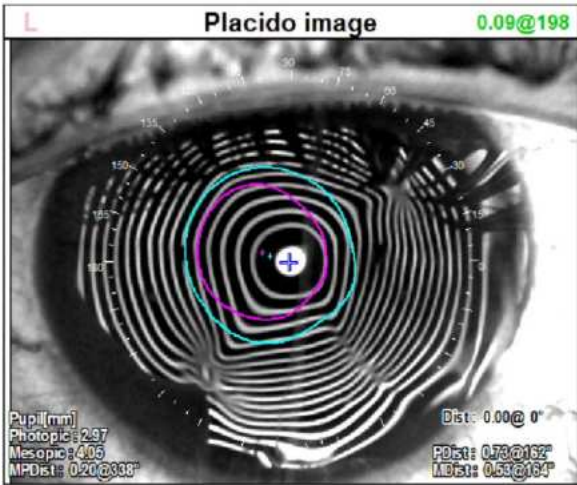
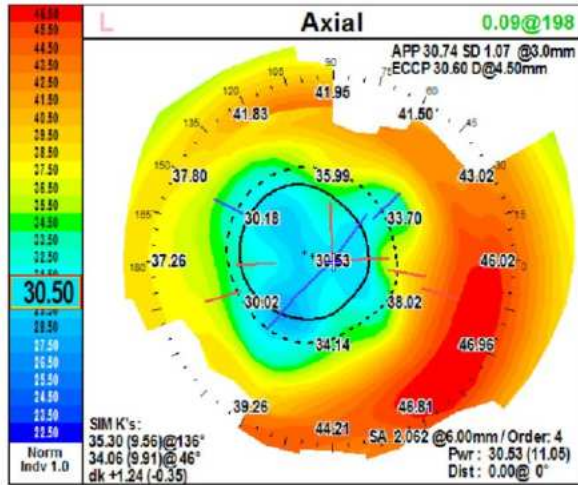
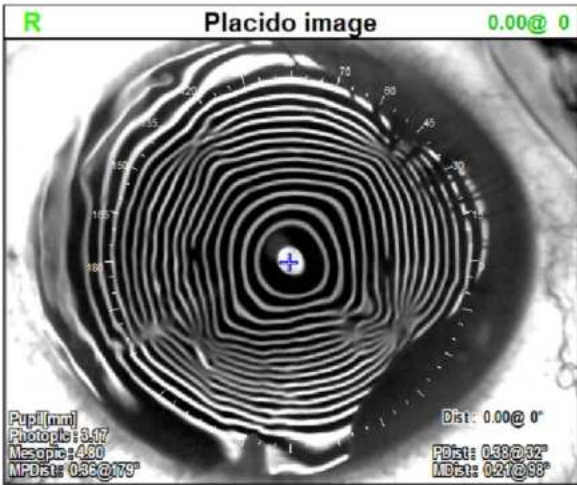
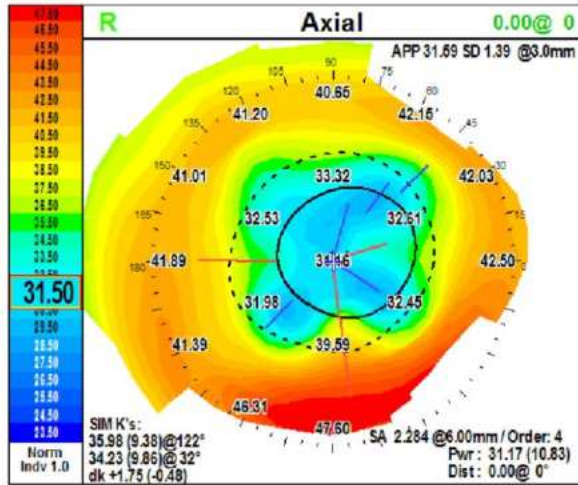
OD -2.0+1.5 x180 “20/25”

OS -0.5+1.25x175 “20/25”

- 2018 Cataract extraction with Alcon Acrysoft 24.5D OU  
Local University Hospital
- 2013 Cross linking OS Local University Hospital
- 1995 RK OU out of state (pre-op Rx: OD -6.25 OS -6.5)

# Case 4: 63 yo RK ectasia, irregular astigmatism, chronic diurnal fluctuation OU “no improvement” after crosslinking (OS) and cataract surgery (OU)

L	12/09/2019 08:30	Comment	L	Diagnosis	L
R	12/09/2019 08:30		R		R



## Case 4: LEFT EYE

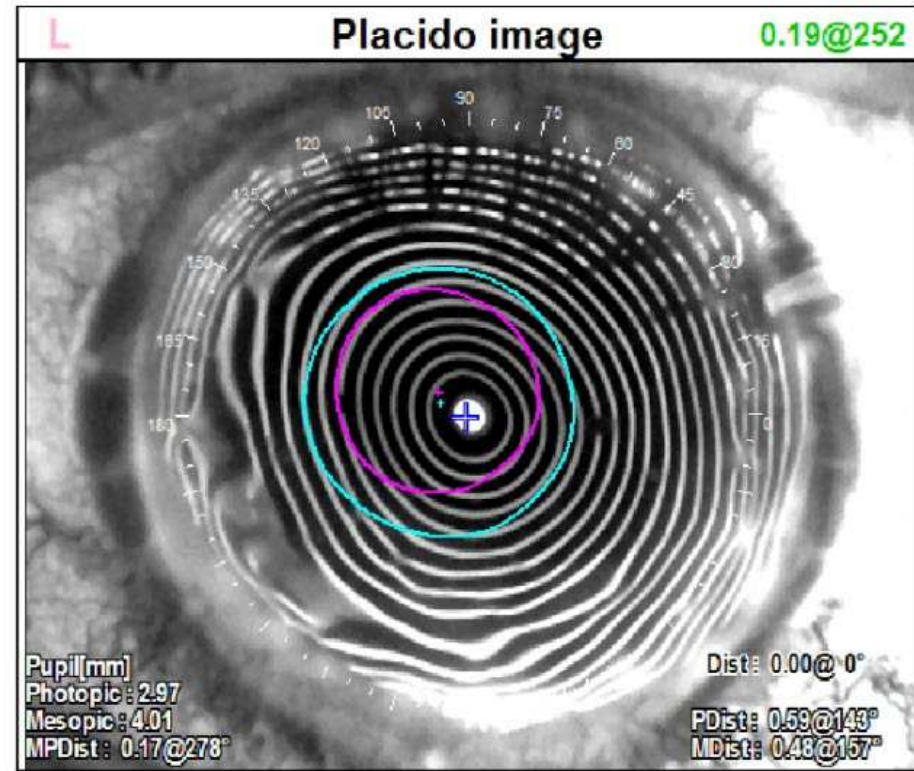
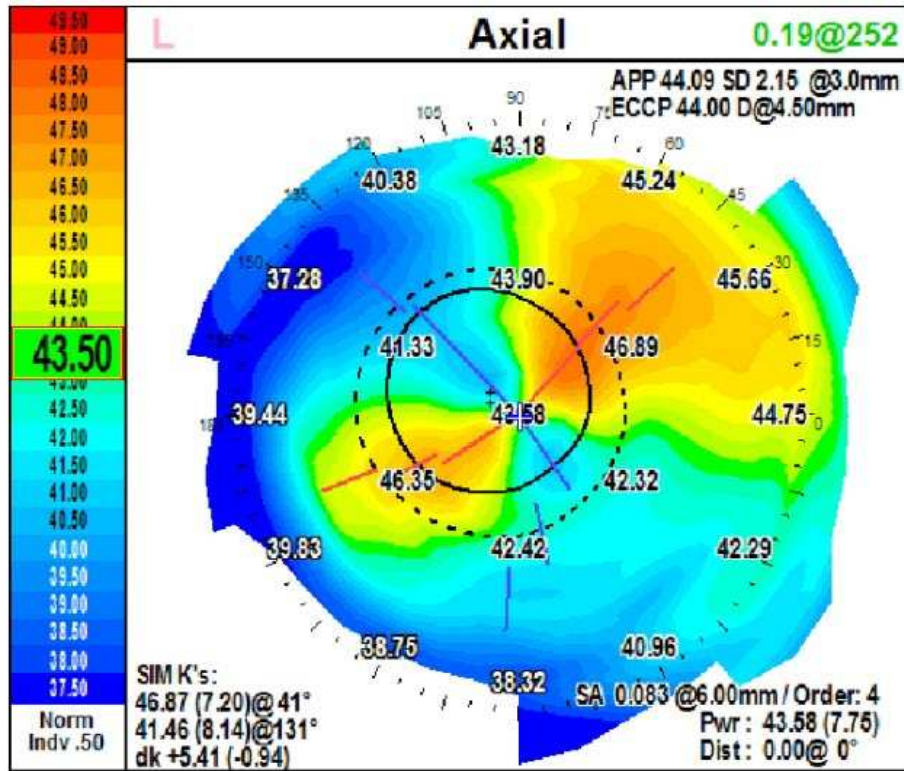
63 yo RK ectasia, irregular astigmatism, chronic diurnal fluctuation OU  
“no improvement after crosslinking (OS) and cataract surgery (OU)”

- 1/21/2020 OS DALK 9.5mm bed/9.75mm donor predescemets dissection multiple perforations at RK incision sites, added ac air, 24bite running suture adjusted under intraoperative keratometer
- 10/21/2020 (9 mos later) OS removed running suture

# Case 4: LEFT EYE

1/15/2021 (one year post DALK, running suture out x 3 mos):

OS -15.75 + 5.0 x 43 20/25 add 2.50 J1





## Case 4:

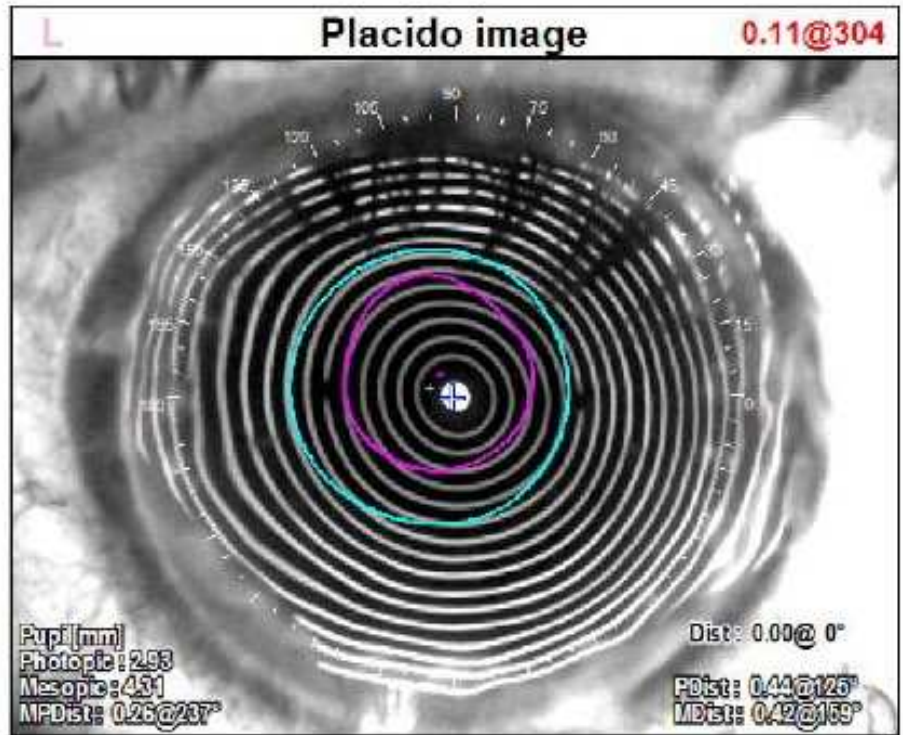
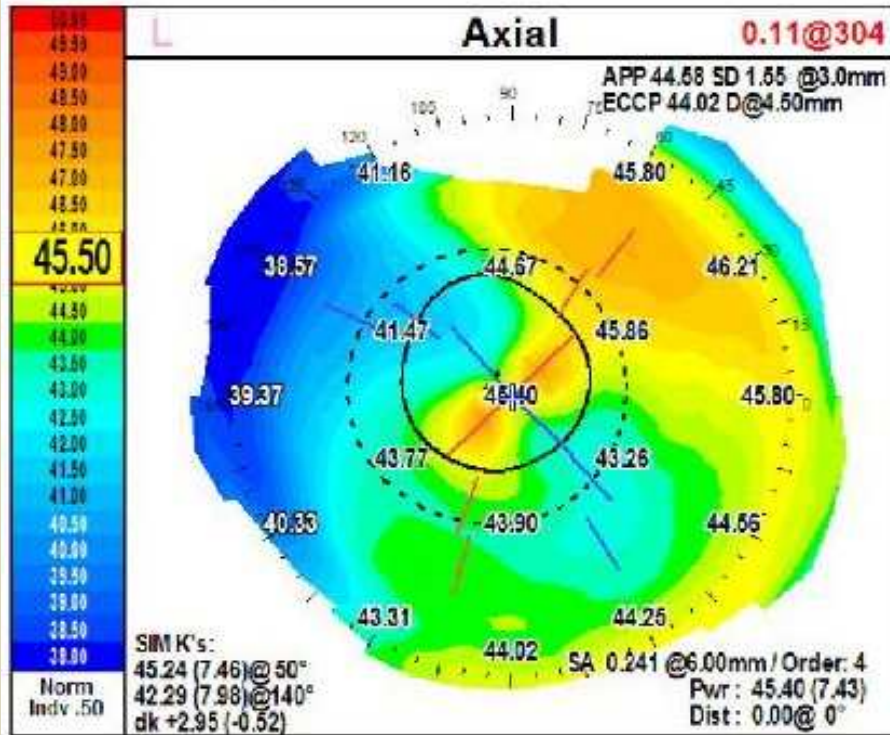
- 3/9/2021 OS:

Exchange Alcon AcrySof IQ SN60WF 24.5D for  
AMO Toric ZCT600 7.5D x 60

# Case 4: LEFT EYE

8/23/2021 OS: (1.5 years after DALK, running suture out x 10 mos, 7 mos after IOL exchange):

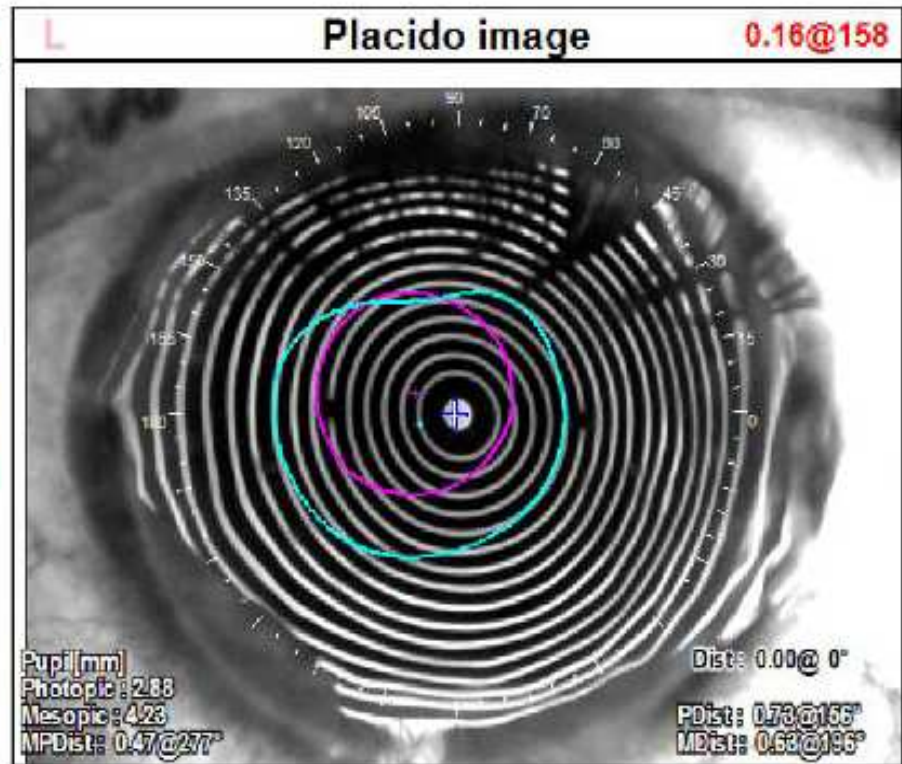
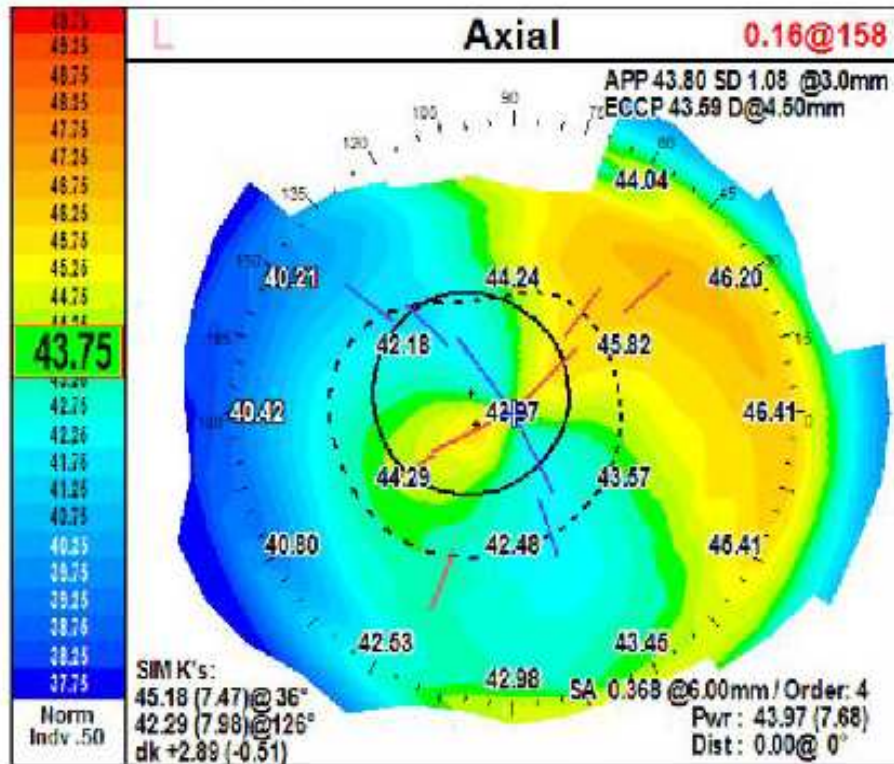
OS UCVA 20/30 -0.5+0.5x008 20/20 add 2.50 J1



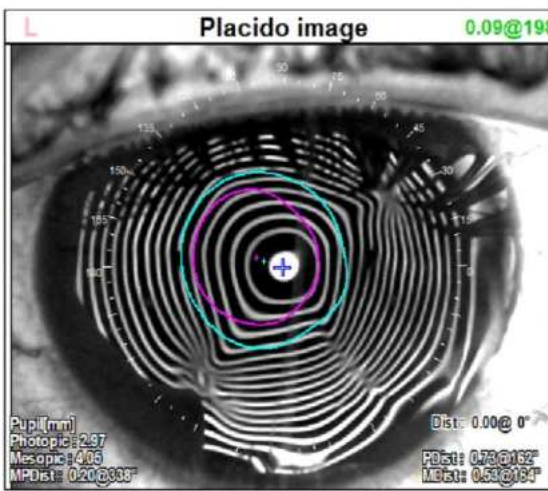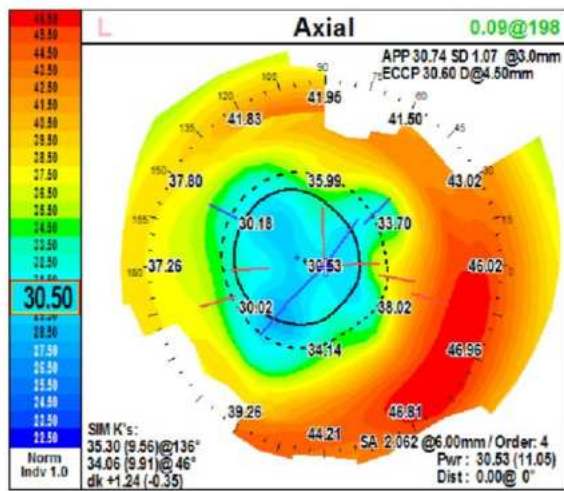
# Case 4: LEFT EYE

2 yrs after DALK, 1yr after IOL exchange:

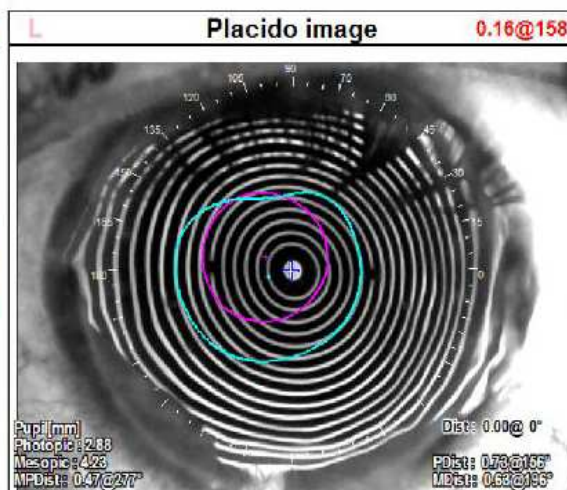
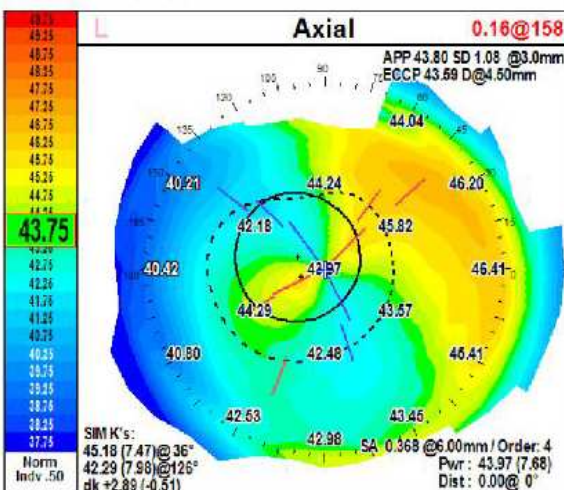
OS UCVA 20/25 -0.5+0.5x008 20/20 add 2.50 J1



# Case 4: LEFT EYE: SUMMARY Pre-op vs. 2 years after DALK (large dia.)



OS: Pre-op DALK 25yrs after RK/CXL/ cataract / high power IOL



OS: 2 yrs after DALK, 14mos after running suture removal, 1yr aft IOL exchange):  
OS UCVA 20/30 -0.5+0.5x008 20/20  
add 2.50 J1

## Case 4: RIGHT EYE

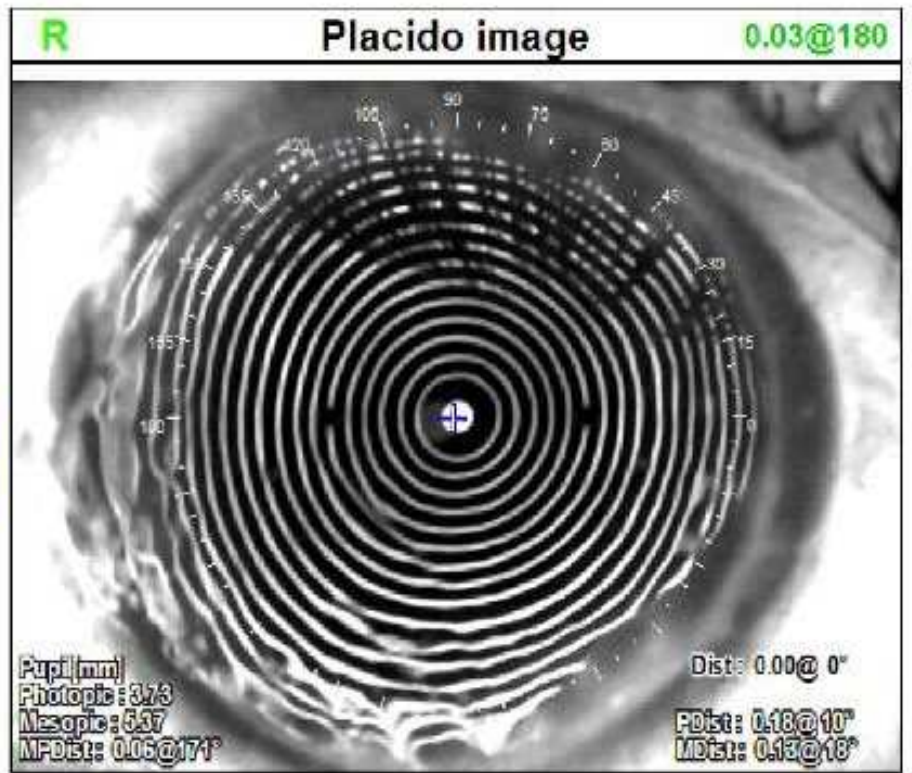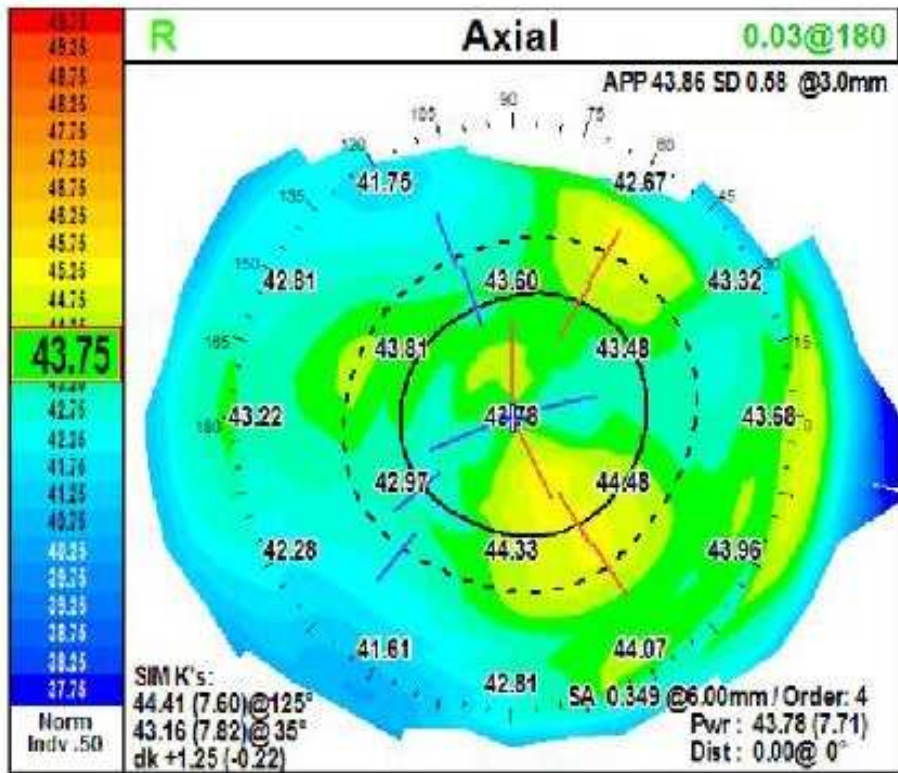
63 yo RK ectasia, irregular astigmatism, poor vision, chronic diurnal fluctuation, cataract surgery with high power IOL. (Due to poor results in other eye after cross-linking, pt had refused cross-linking in this eye)

- 10/5/2021 OD: DALK 9.5mm host/9.75mm donor (donor marked nasal during harvesting, laterality matched) predescemets dissection microperforation at 11:30 and 12:30 periphery adjusted running suture under intraoperative keratometer
- 3/22/2022 (5 mos later) removed running suture

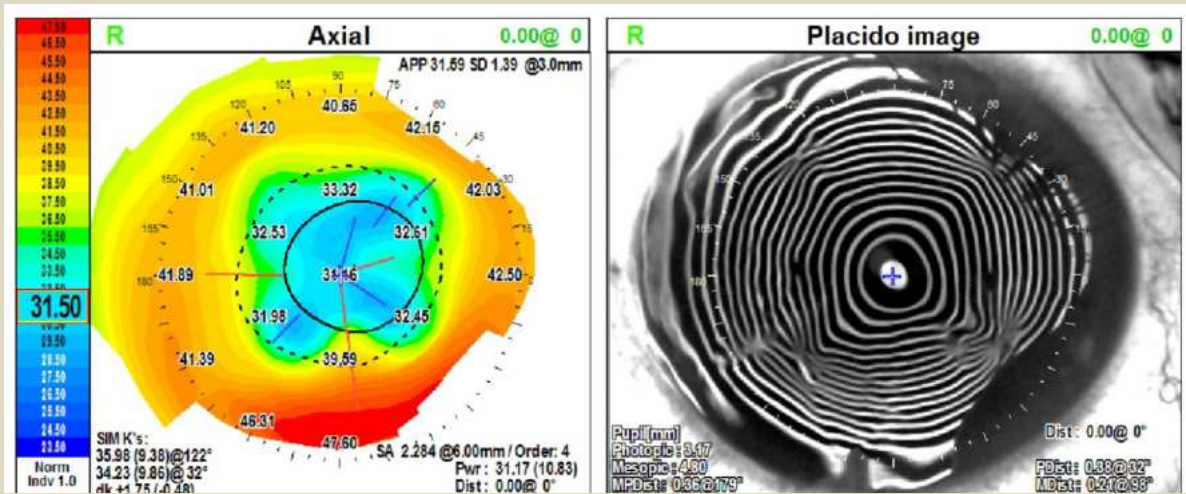
# Case 4: RIGHT EYE: DALK

10/5/2021 DALK, (running suture out x 1 mo):

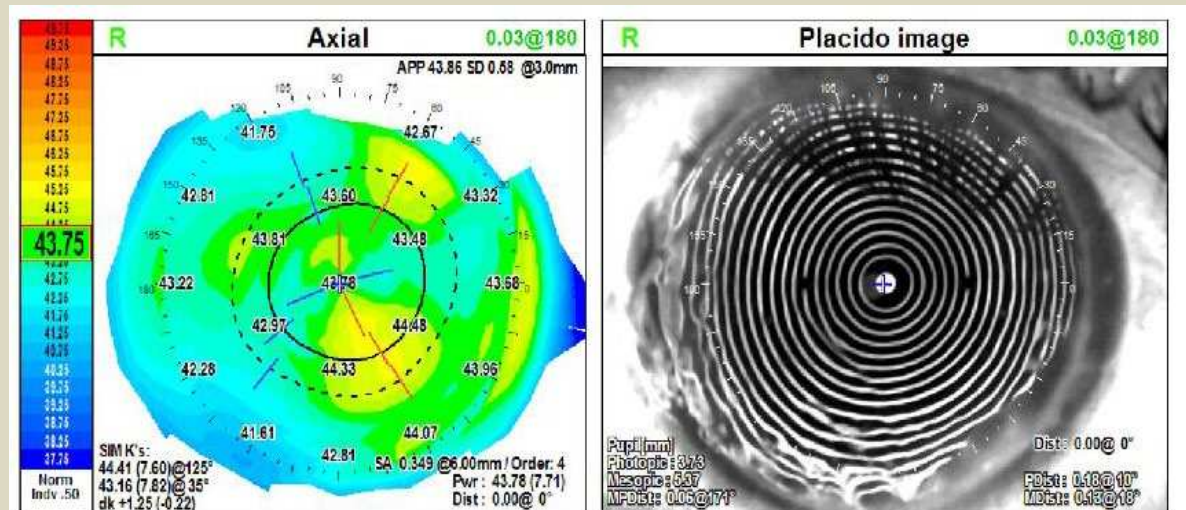
-13.0 + 0.5 x 70 20/25 add 2.50 J1



# Case 4: RIGHT EYE: SUMMARY Pre-op vs. 14 mos after DALK (large 9.5mm dia.)



OD: 27yrs after RK cataract extraction w high (24.5D) power IOL



OD: 14mos after DALK, 9 mos after running suture removal, 6 mos aft IOL exchange w B&L MX60T1.25 9.0 x 125  
 Uncorrected VA 20/25

# Case 4

OS: DALK / IOL Exchange

OD: DALK / IOL Exchange

Outcome: Extremely HAPPY!

- OS UCVA 20/30 -0.5+0.5x008 20/20 add 2.50 J1
- OS visual quality “light years better than my right eye” (since DALK OD performed) despite right eye refracting to “20/25” pre-DALK – c/w poor visual quality/contrast sensitivity). Diurnal fluctuation did not improve after cross-linking but was completely eliminated after DALK.
- OD (before DALK) -2.25+1.50x180 20/25 note flat K’s, high aberration profile c/w “very poor day and even worse night vision” with diurnal fluctuation “for many years”
- OD 10/5/2021: DALK 9.5mm dia laterality matched, marked nasal suture-out astigmatism negligible. After IOL exchange. UCVA 20/25!



# Case 4: Conclusions: RK Ectasia OU “unsuccessful” corneal cross-linking (OS) with subsequent cataract surgery w high power IOL OU OS: Large dia DALK and staged IOL exchange OD: Large dia DALK – IOL exchange pending

After experiencing the results of this fully restorative surgical sequence including high optical quality uncorrected VA OS with complete resolution of diurnal fluctuation this astute patient asked me a series of questions during a post-op exam:

“Were you performing DALK surgery in 2013 when I was instead referred across town for cross linking?”

Answer “yes”

“Well...neither the crosslinking nor the subsequent cataract surgery helped me. I lost 8 years of my life that I could have instead been seeing this well!”

## Discussion:

This patient unnecessarily lived with very poor quality, fluctuating corneas and poor VA for 8 yrs longer than he needed to.

At best, cornea cross-linking is theoretically designed to “stabilize”...it is NOT restorative, it is not a “Refractive Surgical procedure” in that its effect on cornea curvature is NOT predictable. It is not stable over time, it does NOT meaningfully improve higher order aberrations or irregular astigmatism, it will potentially flatten K’s further (though I have also seen steepening), it does not eliminate, but has been reported to possibly “improve” diurnal fluctuation. Large Diameter (9.5-10mm) DALK, in my hands, is not only fully restorative, it also “qualifies” as a refractive surgical procedure when combined with a running adjustable 24 bite suture to “train” the cornea to be a better sphere. Suture-out cornea donor graft curvature is VERY stable over MANY years! Residual astigmatism if present is REGULAR and can be predictably debulked with single or paired scleral tunnel incisions on steep axis 2mm into graft stroma but NOT penetrating into eye to avoid detaching Descemet’s membrane. Diurnal fluctuation is ELIMINATED!

Cross-linking makes subsequent manual layer by layer stromal dissection more difficult because cross-linked stromal collagen has a notably firmer texture often requiring two crescent blades dulling them faster than dissecting “virgin” stroma. It is generally also more difficult to achieve a big bubble during DALK in a cross linked cornea.

Five years after “unsuccessful” cross-linking OS, this patient had cataract surgery OU which predictably would not improve visual function in either eye. Because of the lack of regional DALK capability and generally high conversion rates to PKP (with all its limitations) there is a strong tendency to perform cataract surgery with a high power IOL to compensate for excessive cornea flattening and irregularity rather than first definitively restoring the cornea with DALK. After cataract surgery with IOL in such a case, Snellen Visual acuity is misleading – note this pt refracted to “20/25” in each eye after cataract surgery but was miserable due to poor visual quality and diurnal fluctuation. When this approach “fails”, and a DALK becomes necessary, the patient is subjected to an additional intraocular procedure (IOL exchange) required to achieve final “optical rescue”.

My overall DALK conversion rates to PKP for all indications are negligible. Over the last 12 years 99.5% of all attempted DALK were completed, only 2 had to be converted to PKP (10 yrs ago). During this same period, I have had zero conversions to PKP when performing DALK in RK ectasia eyes. My cornea fellowship-trained partner, Daryl Kaswinkel, MD has nearly the same very low rates of conversion to PKP during DALK.

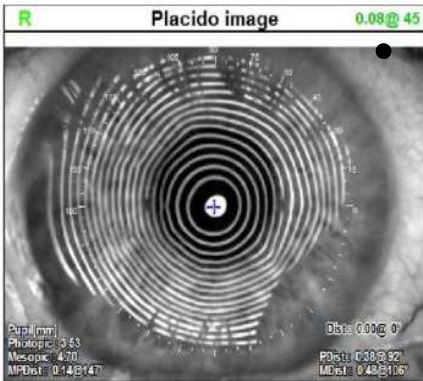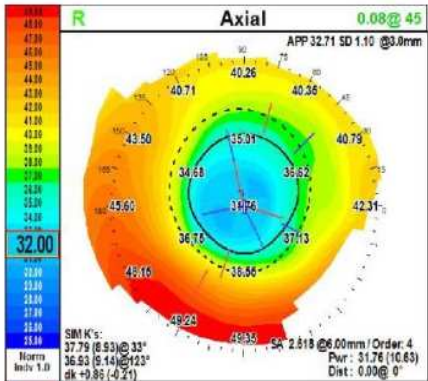
# Case #4 Patient testimonial

## Large diameter DALK: Cornea Restoration OU for RK ectasia:

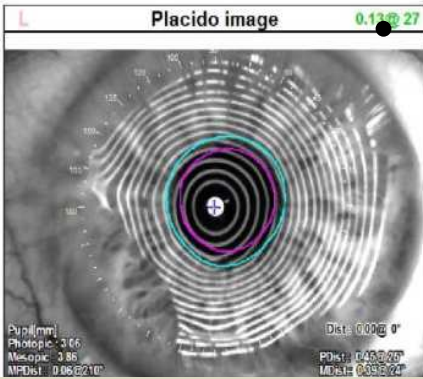
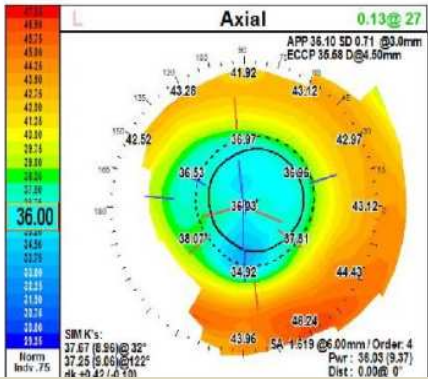
- Video: Patient testimonial

Case 5: 71 yo male c/o night glare, very poor night vision, visual fluctuation, requiring scleral contacts x 10yrs, now intolerant. Progressive hyperopia 2008 OD: cataract extraction with Alcon SN60WF 24.0 in N.C. OS: phakic 1990 OU Radial Keratotomy in North Carolina

L	10/21/2019 08:15	Comment	L	Diagnosis	L
R	10/21/2019 08:15		R		R



OD: +2.75+3.75x177 20/50



OS: +2.0+1.25x008 20/40

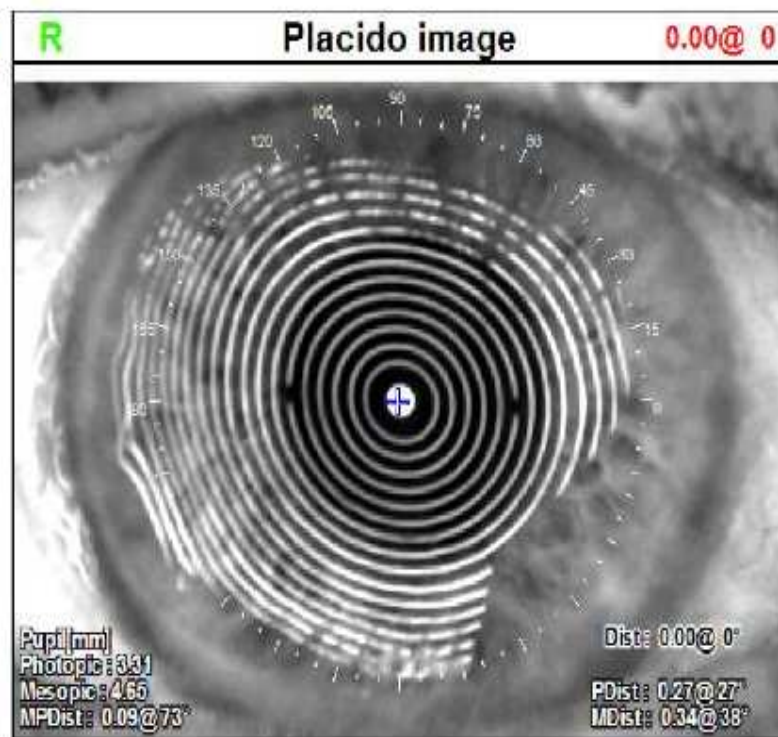
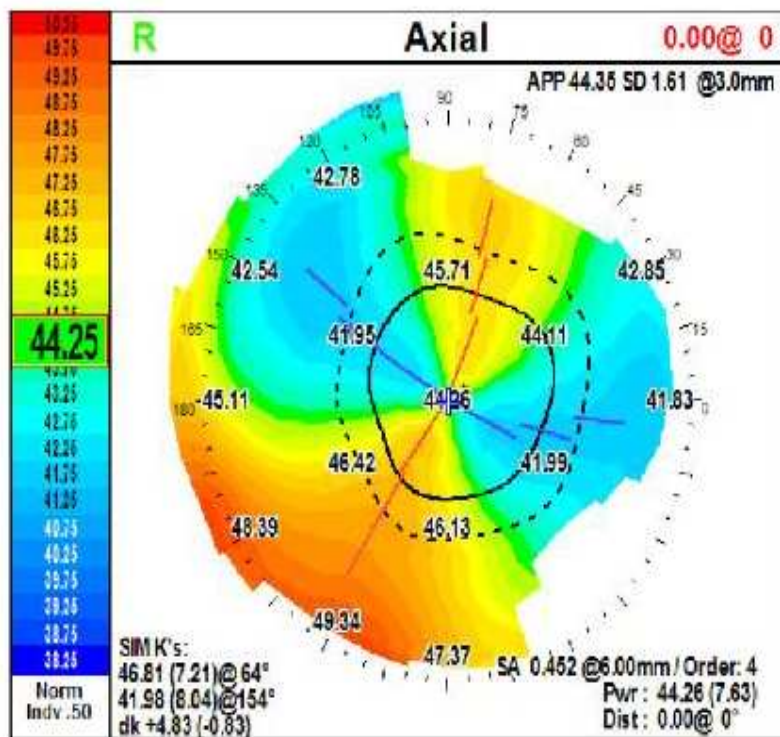
# Case 5: Right Eye

5/2022 -10.75+3.50x58 20/25 (successfully wearing scleral lens while anticipating IOL exchange)

9/2020 OD Removed running suture

10/2019 OD DALK 10.0mm

L	05/25/2022 08:05	Comment	L	Diagnosis	L
R	05/25/2022 08:04		R		R

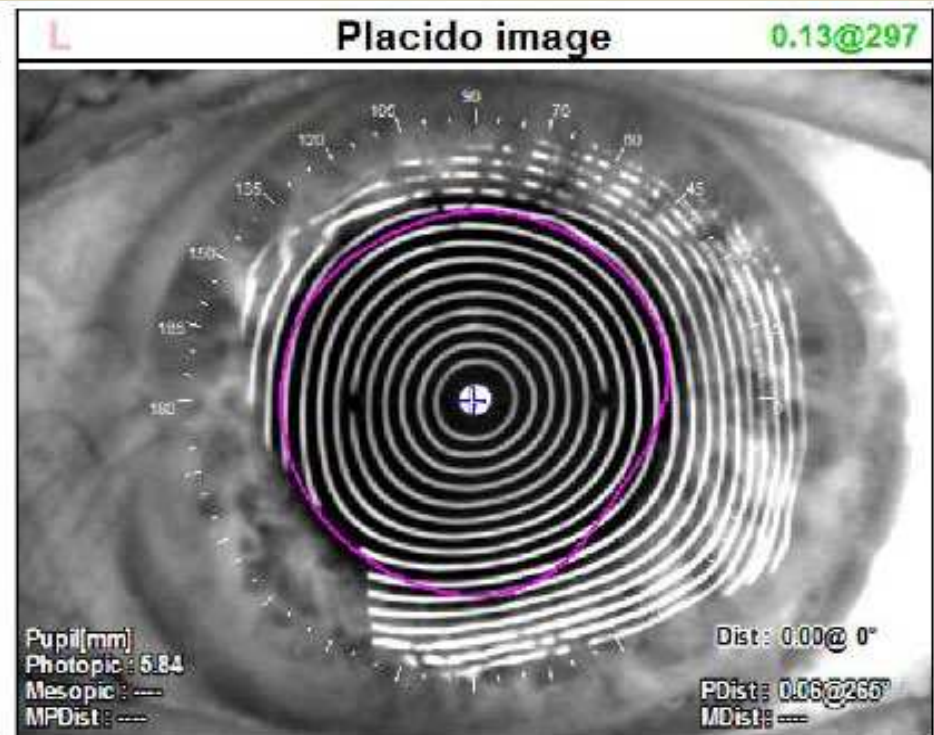
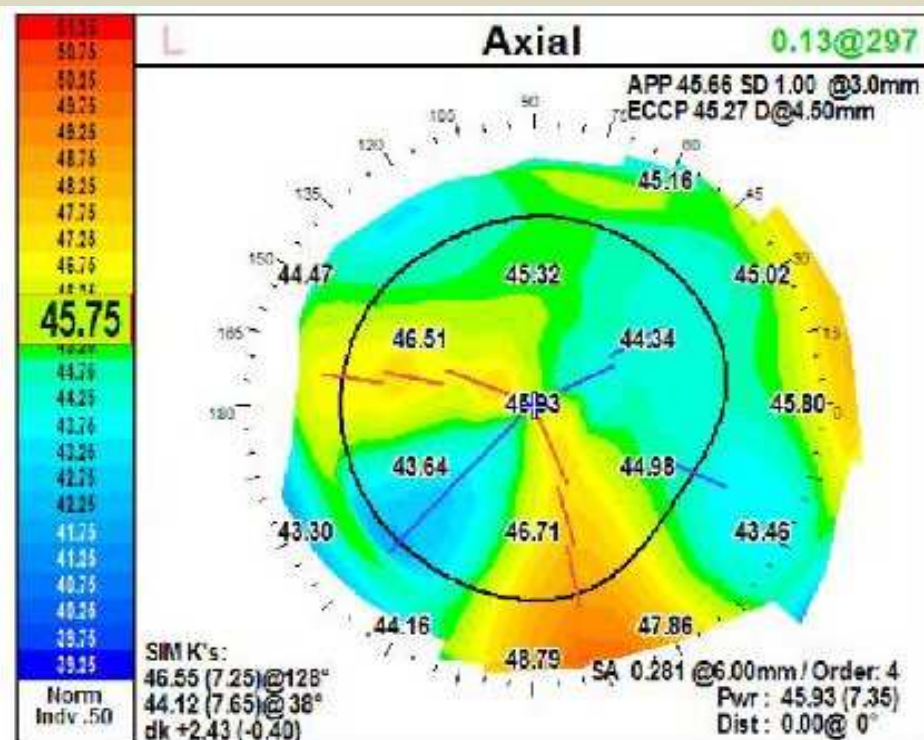


## Case 5: Left eye

9/2022 -4.25+1.0 x 150 20/50 (cataract) note topo below – non-orthogonal astigmatism

5/2021 removed running suture

9/2021 DALK 10.0mm/10.5mm dia donor laterality matched, nasal marked/oriented



Case 5: Left EYE

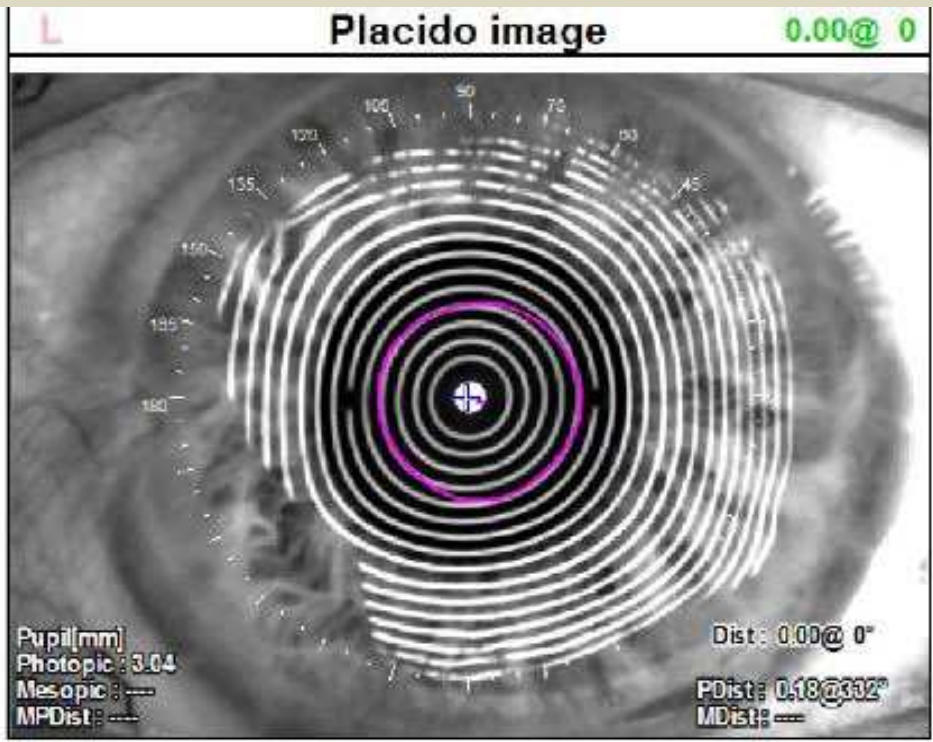
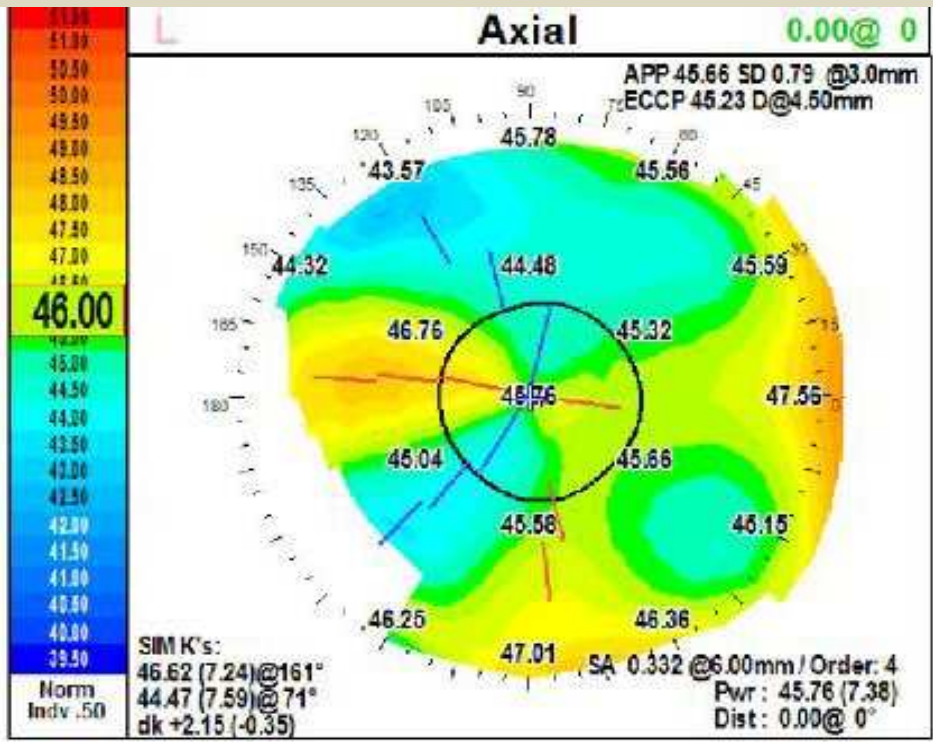
1/9/2023 Uncorrected VA 20/25 -1.0+0.5x36 20/20 "EXTREMELY HAPPY!"

(topo below: note debulked cylinder)

12/20/2022 cataract ext w B&L50T3.50 12.5D x 160

9/2022 AK - inferior scleral pocket lamellar incision 1mm posterior to limbus, 7mm arc length centered on x 280 deg 2mm into graft but NOT penetrating into anterior chamber to avoid possible descemets membrane detachment

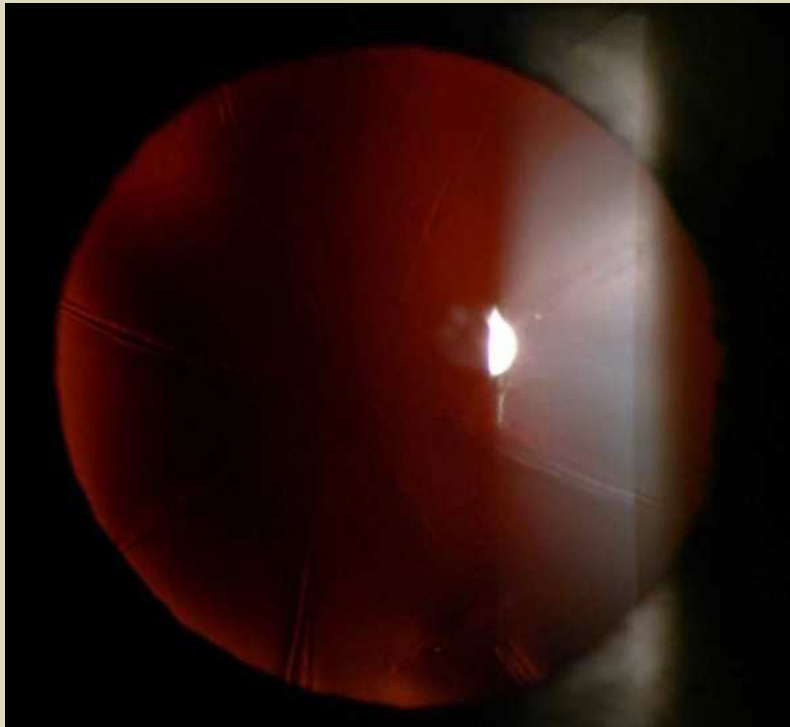
9/2021 DALK 10.0mm/10.5mm dia donor laterality matched, nasal marked/oriented



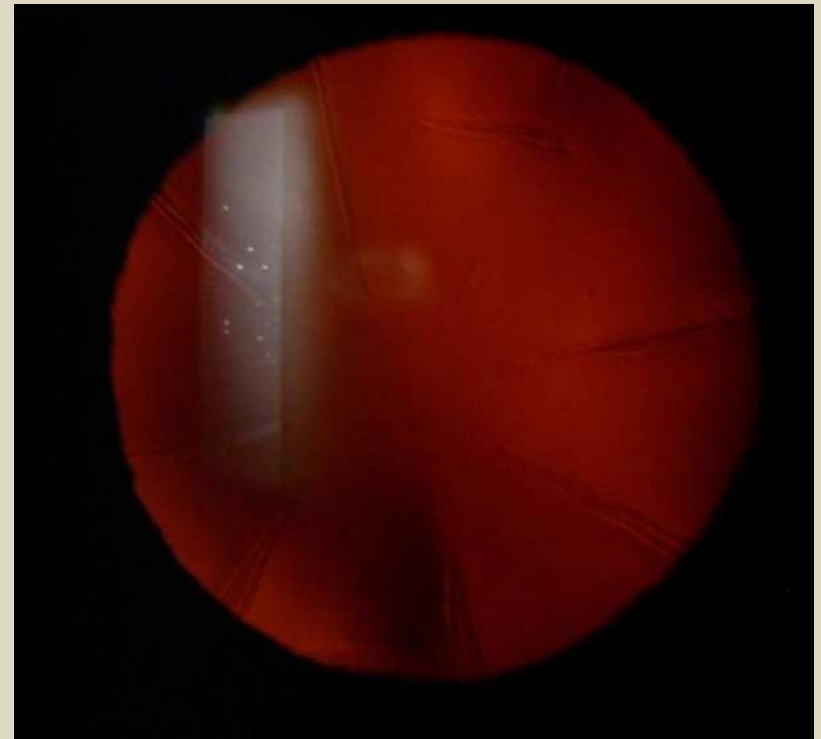
Case #6 55yo male

Radial Keratotomy (RK) both eyes 1993 Illinois  
c/o very poor night vision, glare, diurnal fluctuation

- Right Eye



Left Eye

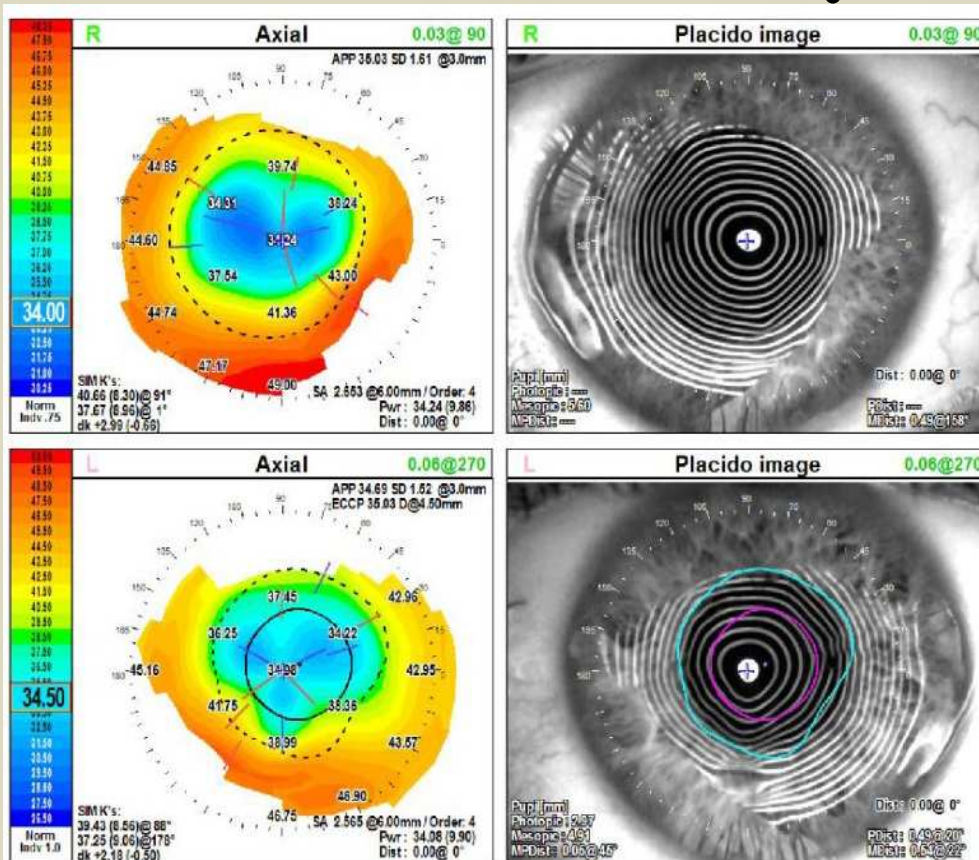


Case #6 55yo male

Radial Keratotomy (RK) both eyes 1993 Illinois

c/o very poor night vision, glare

topography OU: irregular astigmatism, very flat central K's



OD

-3.50+3.25x90 20/40

OS

-0.5+2.25x45 20/30



Case #6 55yo male

OS: visual quality/night vision “dramatically improved – superb visual clarity!”

9/2022 OS: topography: restored normal K’s, eliminated irregular astigmatism

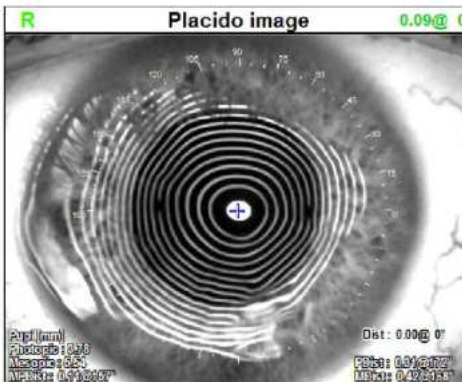
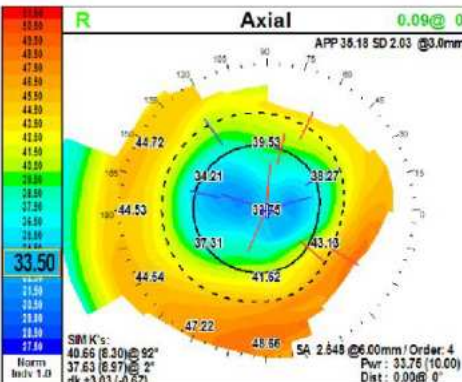
7/2022 OS: Cataract ext w Toric B&L MX60T4.25 13.5 x 95

2/2022 OS: removed running corneal suture

5/2021 OS: DALK 9.5mm bed/9.75mm donor predescemets deep dissection, no perforations

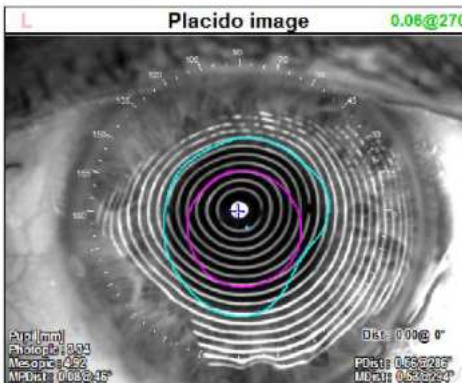
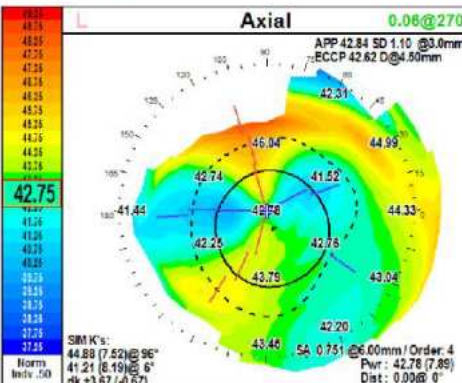
1993 Radial Keratotomy (RK) OU

L	09/02/2022 10:13	Comment	L	Diagnosis	L
R	09/02/2022 10:13		R		R



OD

-3.50+3.25x90 20/40



OS

-1.75+2.25x84 20/30

Case #6 55yo male

visual quality/night vision “dramatically improved after only 3 wks!”

11/29/22 OD topography: restored normal K's, note 3.7D w-t-r regular astigmatism cylinder – suture “in”

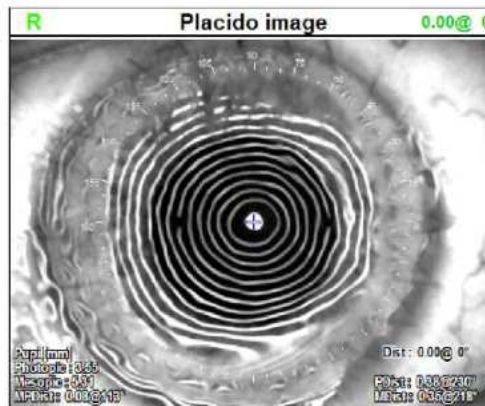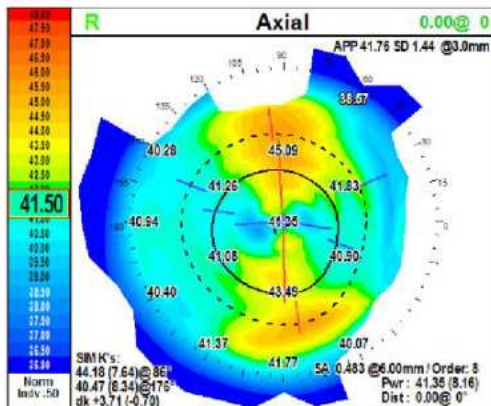
11/8/2022 OD DALK 9.5mm bed/9.75mm donor laterality matched nasal marked big bubble no perforations

24 bite running suture adusted under intraoperative keratometer

5/2021 OS: DALK 9.5mm bed/9.75mm donor predescemets deep dissection, no perforations

1993 Radial Keratotomy (RK) OU

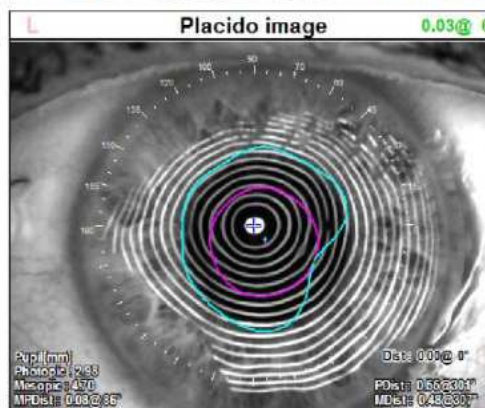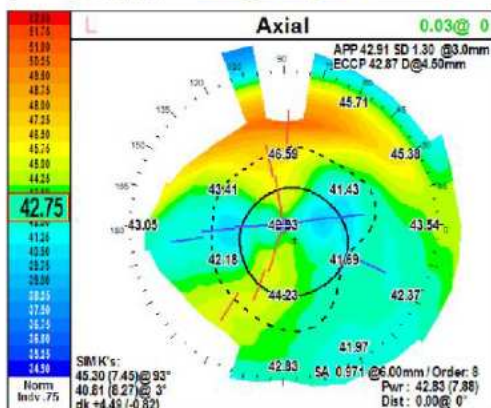
L	11/29/2022 12:46	Comment	L		Diagnosis	L	
R	11/29/2022 12:46		R			R	



OD

Uncorrected VA:20/200

-8.25+4.5x94 20/30



OS

Uncorrected VA:20/40

-0.5+2.25x45 20/30

Case #6 55yo male

visual quality/night vision “dramatically improved – superb visual clarity!”

topography OU: restored normal K’s, eliminated irregular astigmatism

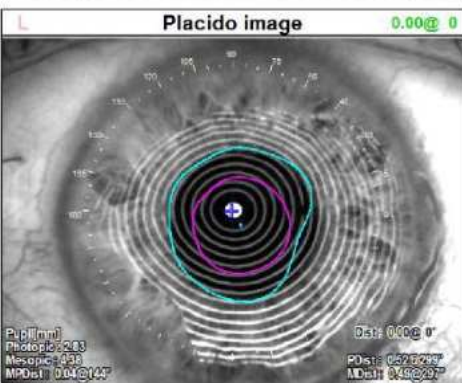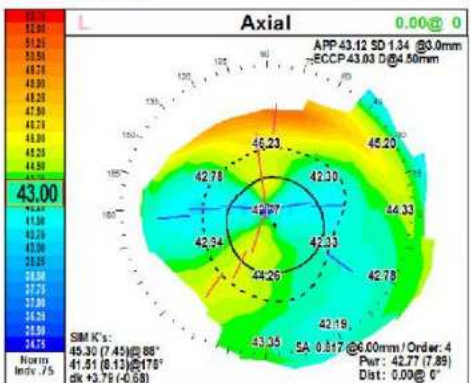
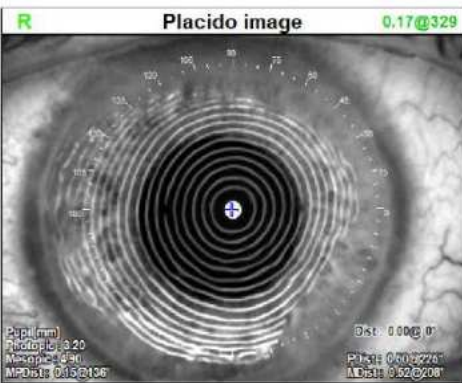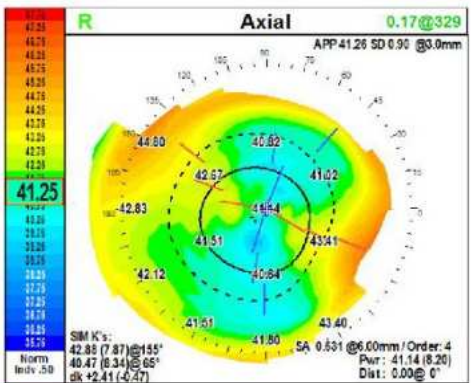
3/2024 OD topography : restored normal K’s, regular astigmatism suture “out” scheduled for LAL

11/2022 OD DALK 9.5mm bed/9.75mm donor laterality matched nasal marked big bubble no perforations

5/2021 OS: DALK 9.5mm bed/9.75mm donor predescemets deep dissection, no perforations

1993 Radial Keratotomy (RK) OU

		Technician			
03/04/2024 08:57	Comment	L		Diagnosis	L
03/04/2024 08:57		R			R



- OD
- Uncorrected VA:20/150
- -8.75+2.75x167 20/30
- Scheduled for LAL
  
- OS
- Uncorrected VA:20/40
- -1.5+1.25x75 20/30

# Case 6: Conclusion

- OD: Optical “rescue” planned cataract surgery with appropriate IOL to attempt to achieve near emmetropia
- OS: could consider AK-scleral pocket incision to debulk residual cylinder and improve uncorrected VA
- After fit with temporary soft toric contact lenses received following text message from pt:

“eyes super sharp with temporary contact right eye and glasses – it’s been 30 yrs since I’ve seen like this. I can again read road signs. Night vision is a joy again – Thank you!”

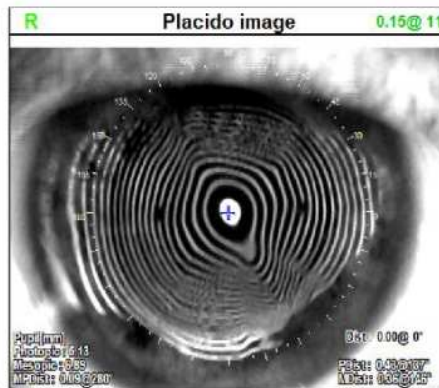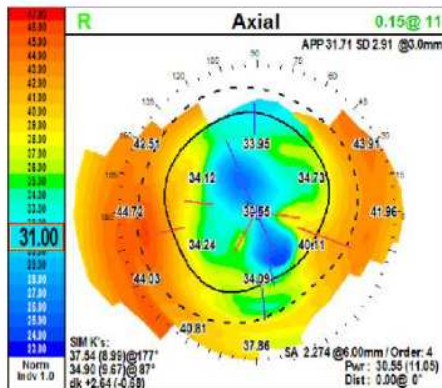
Case #7 63yo female

Radial Keratotomy (RK) both eyes 1994

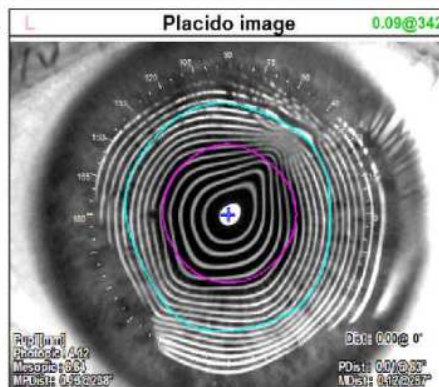
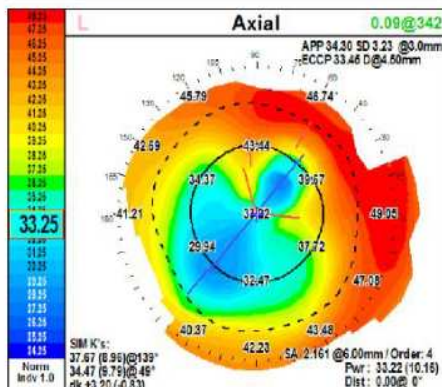
c/o very poor night vision, glare

topography OU: irregular astigmatism, very flat central K's

L	06/14/2023 14:08	Comment	L		Diagnosis	L	
R	06/14/2023 14:08		R			R	



+6.5+2.0 x 46 20/40



+5.0 +3.5 x 142 20/30

Case #7 63yo female

visual quality/night vision “dramatically improved!”

2/26/2024 OS topo below (wintering in Florida)

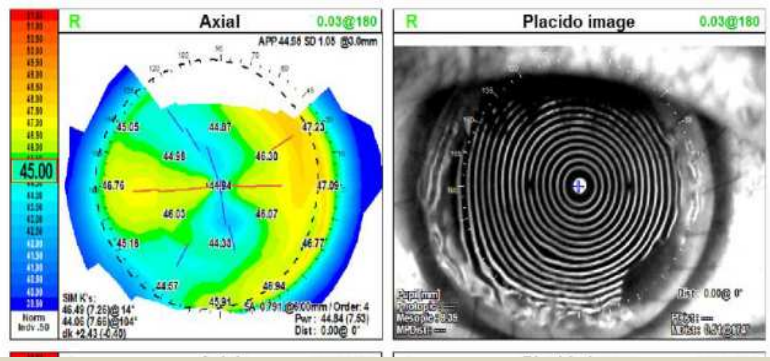
12/2023 OS: DALK 10.0mm bed/10.0mm donor predescemets deep dissection, no perforations

11/27/23 OD topo below

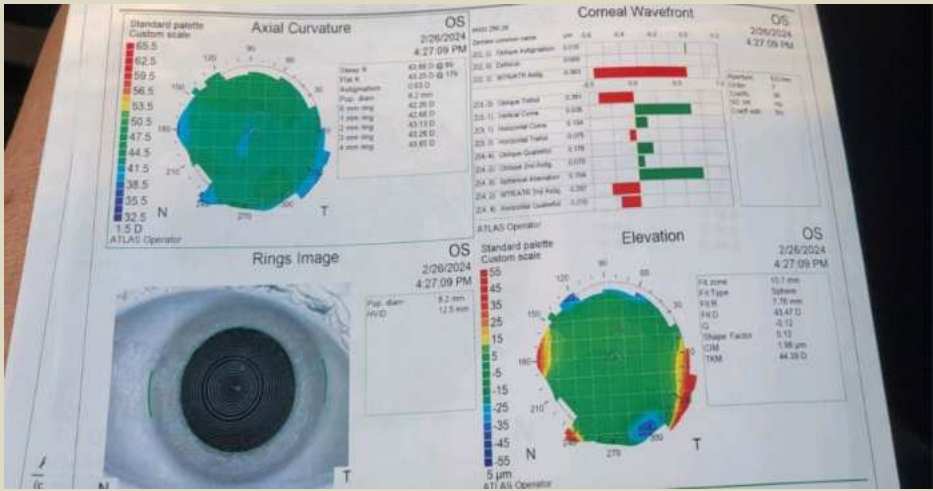
8/2023 OD: DALK 10.0mm bed/10.0mm donor predescemets deep dissection, no perforations

1994 Radial Keratotomy (RK) OU

		Technician	
L	11/27/2023 11:46	Comment	L
R	11/27/2023 11:46		R
		Diagnosis	



- OD -6.0+3.75x005 20/25



- OS UCVA 20/40 spherical topography! Image from MD seen while wintering in Florida. Not yet refracted