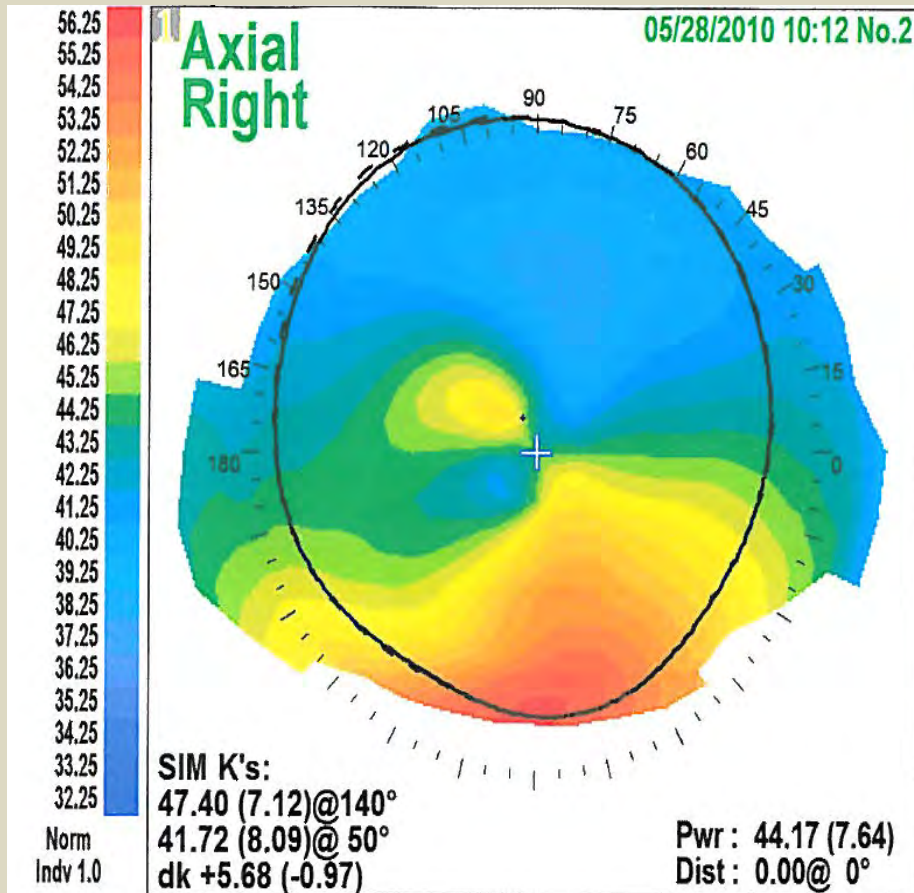


Case #1:

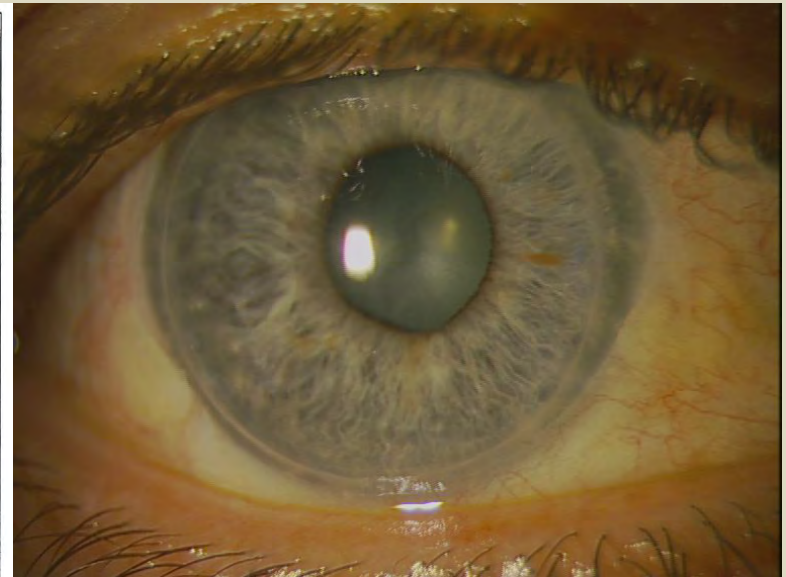
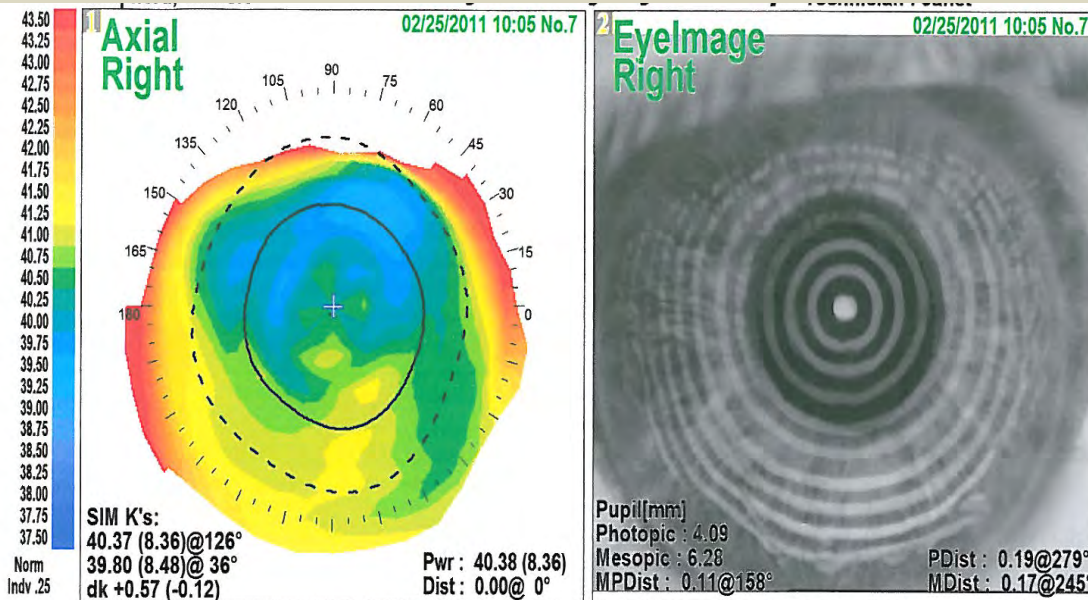
LASIK Ectasia: 48yo male, CL intol
-7.0 + 7.0 x 20/50



Case #1:

OD: DALK 9.5mm dia: 8 mos post-op
(2 mos after suture removed)

+1.25 + 1.5 x 175 x 20/20-



CASE #2:

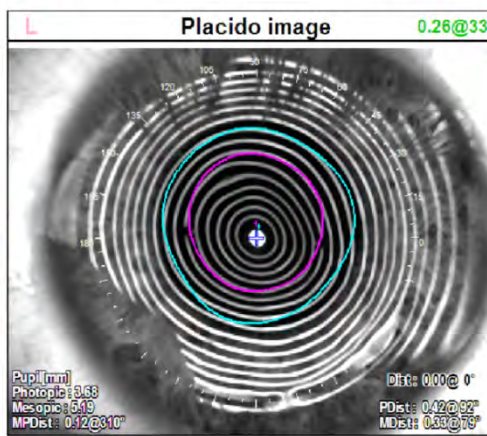
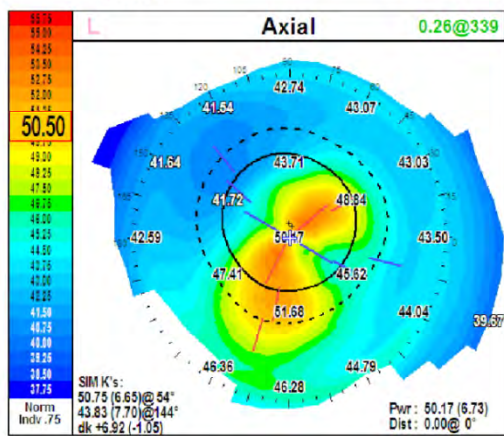
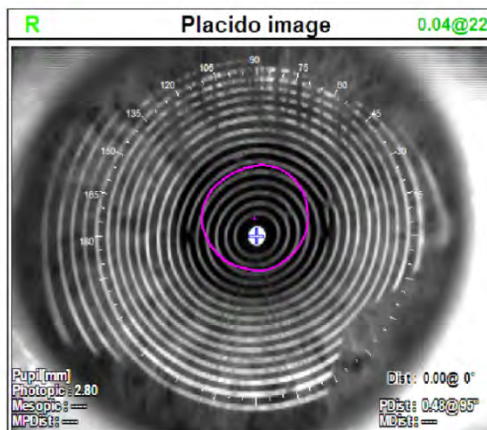
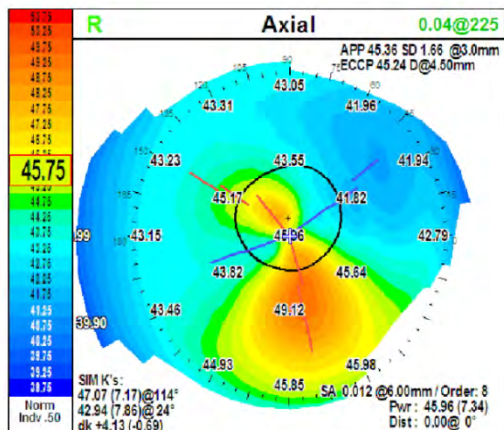
2/2016: 33 yo male referred 3 mos after cross linking OS (right eye not x-linked)

“I still cannot see out of my left eye and vision very poor right eye – especially at night”

12/2015 OS: Corneal Cross-linking (performed by original LASIK surgeon)

2008 LASIK OU for low myopia (-3.0D OU) “vision OK for for initial 4 yrs” then developed ectasia OU

L	02/17/2016 16:08	Comment	L	Diagnosis	L
R	02/17/2016 16:08		R		R



- OD: -2.50+2.0x165 20/40

- OS: 20/150

Case #2:

1/2022 Topo below: wearing soft contact lenses OU

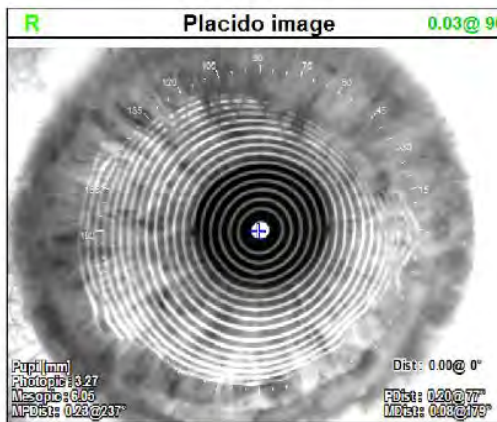
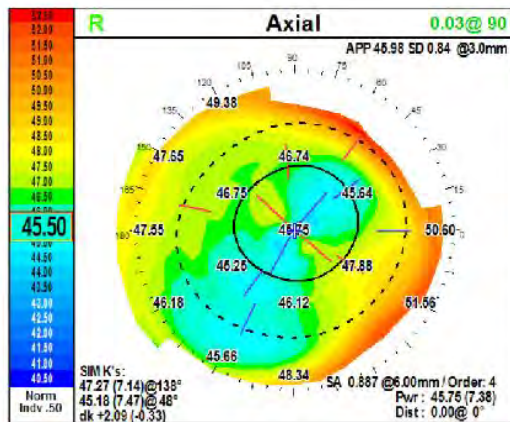
12/2019 suture removed

6/2019 OS: DALK 9.5mm 24 bite running suture

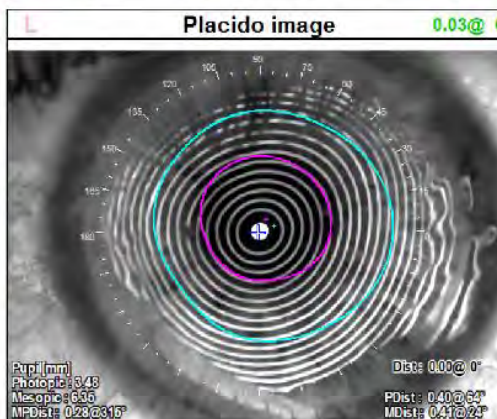
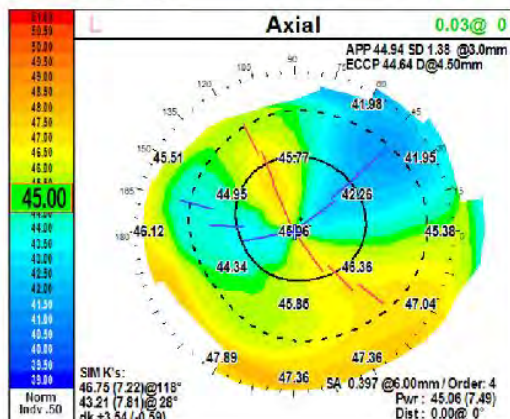
12/2016 suture removed

6/2016 OD DALK 9.5mm 24 bite running suture

L	01/31/2022 08:51	Comment	L	Diagnosis	L
R	01/31/2022 08:51		R		R



-7.0+2.75x141 20/20



-7.0+4.5x129 20/20

Case #2:

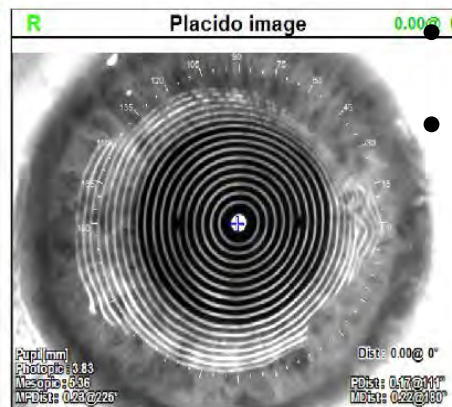
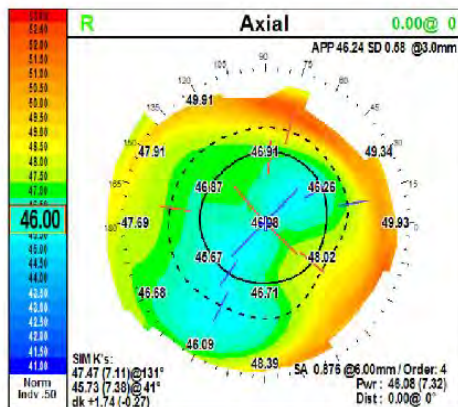
11/2022 Topo below EXTREMELY HAPPY!

2/2022 Staar Toric ICL OD: 13.2 -8.0/2.5 OS: 13.2 -7.5/4.0

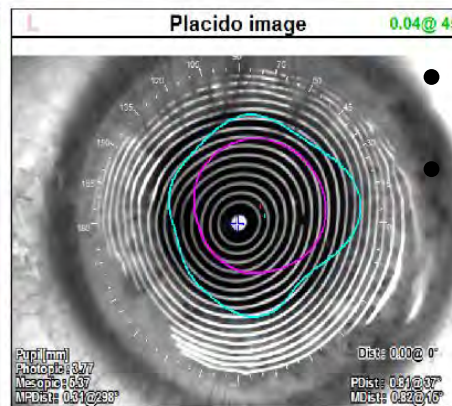
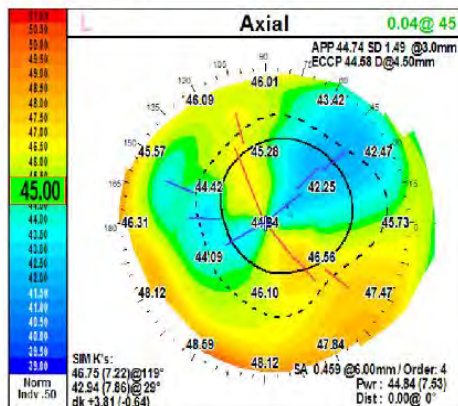
6/2019 OS: DALK 9.5mm

6/2016 OD DALK 9.5mm

Date	L	R	11/09/2022 14:09	Comment	L	R	Diagnosis	L	R
			11/09/2022 14:09						



OD: Uncorrected VA 20/20
 -0.25+0.5x136



OS: Uncorrected VA 20/25
 -1.0+1.0x100 20/20-

CASE #3:

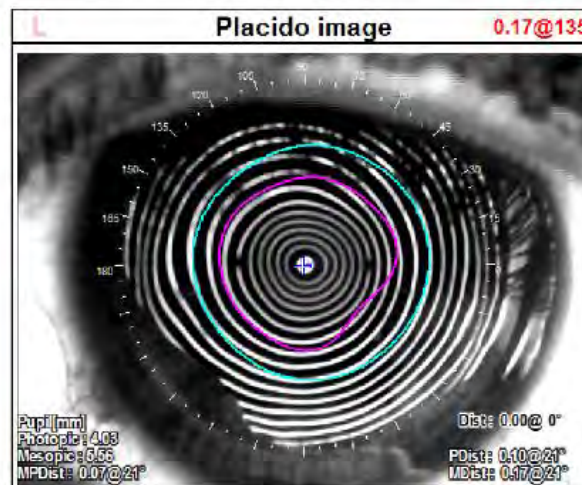
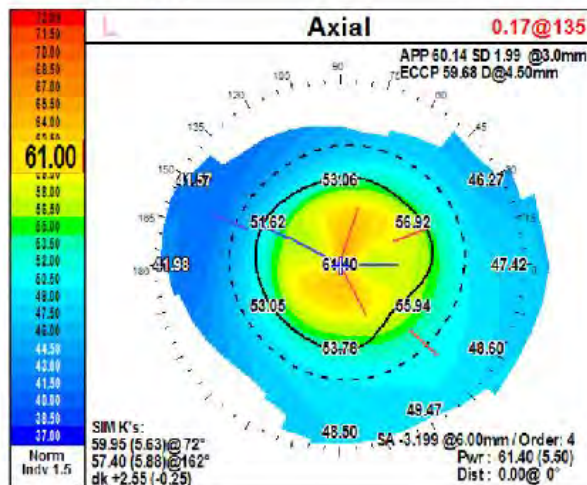
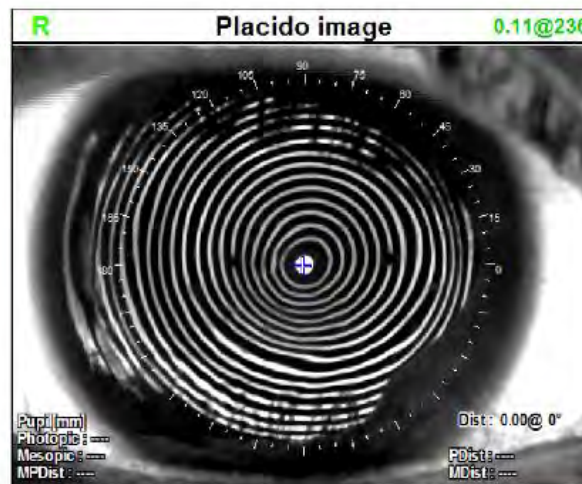
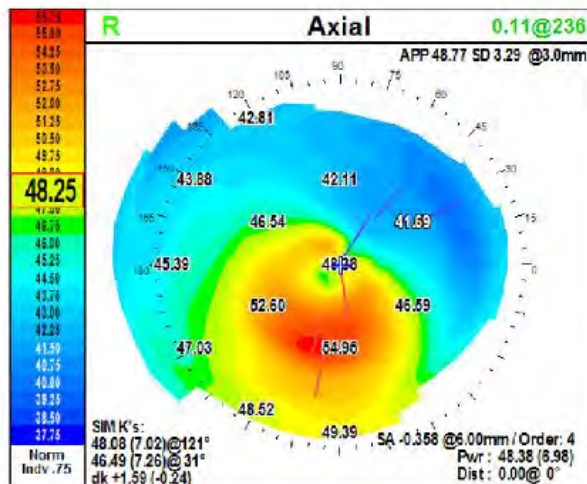
33 yo female referred with Lasik Ectasia OU “very poor night vision”

2013 Vitamin A trial

2/2011 Cornea Cross Linking OS OSU “didn’t help”

1998 LASIK OU for myopia “vision OK for for initial 10 yrs” then developed ectasia OU

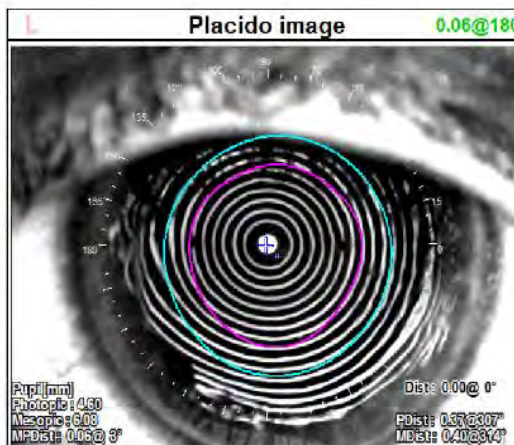
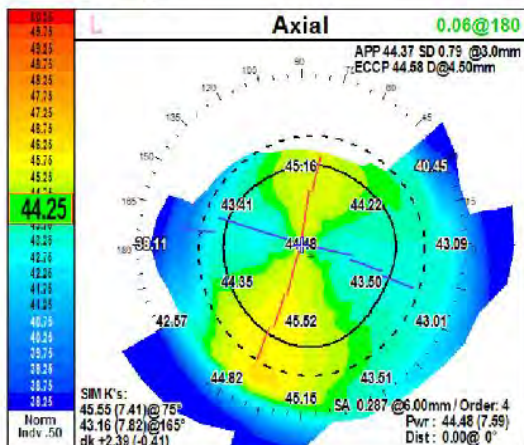
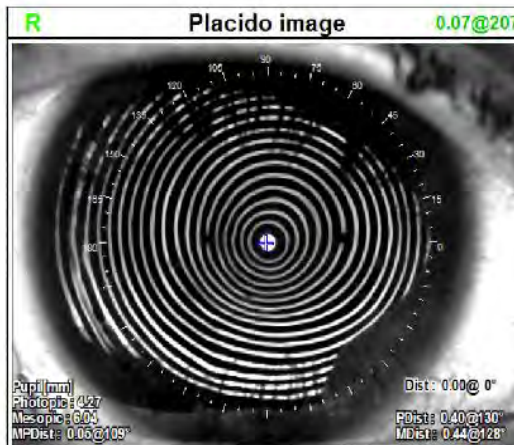
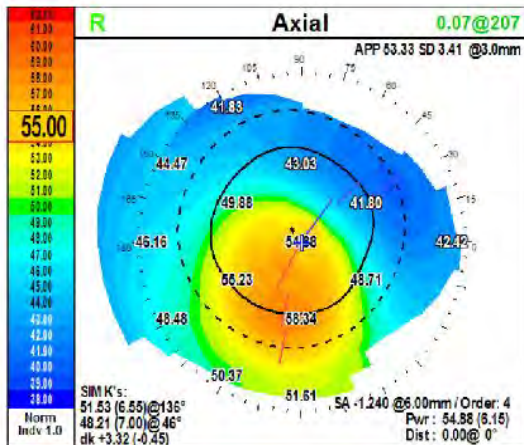
L	02/22/2021 15:52	Comment	L	Diagnosis	L
R	02/22/2021 15:52		R		R



Case #3

3/6/2023 topo below. VERY HAPPY w dramatic visual improvement OS ! Scheduling DALK OD
 2/2023 Removed running suture OS
 3/2021 OS DALK 10mm donor/10mm bed

03/06/2023 16:34		L			L
03/06/2023 16:34	Comment	R		Diagnosis	R



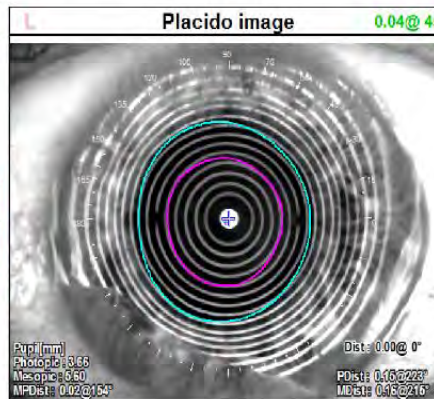
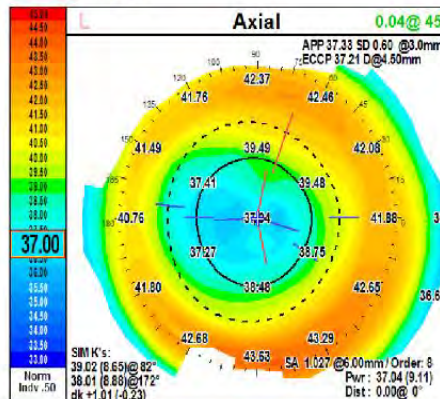
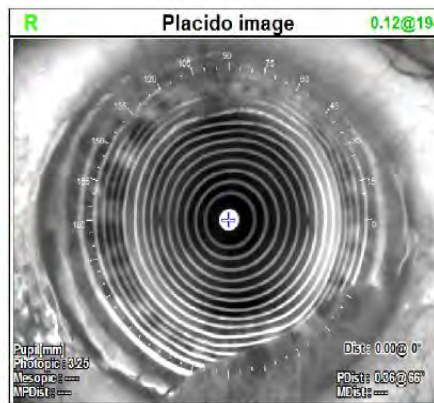
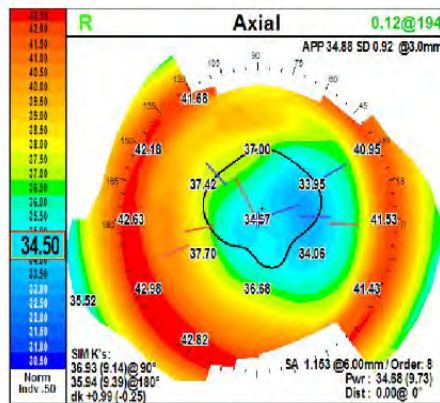
- Thrilled!!
- UNCVA 20/40-
- -1.5+2.0x80 20/20

Richard Erdey, MD

Case #4

8/2021: 64 yr old female referred c/o poor vision / severe night glare both eyes last 22yrs “ever since PRK” both eyes. Told she developed “central corneal haze” both eyes and “nothing they could do”
 1999 OD undercorrection added paired corneal intacs
 1999 PRK high myopia (-13.0 both eyes)

L	09/10/2021 09:07	Comment	L		Diagnosis	L	
R	09/10/2021 09:07		R			R	



Right: (Dominant)

- uncorrected VA 20/30
- -0.25+1.0x96 20/30
- Glare 20/100
- Very flat central K's (35D)
- central corneal haze
- Paired intacs


LEFT

- Uncorrected VA 20/150
- -3.0+1.75x86 20/40
- Glare 20/400
- Very flat central K's (37D)
- Central corneal haze

Case #4

8/2021: 64 yr old female referred c/o poor vision / severe night glare both eyes last 22yrs “ever since PRK”. Told she developed “central corneal haze” both eyes and “nothing they could do”
1999 OD undercorrection added paired corneal intacs
1999 PRK high myopia (-13.0 both eyes)

Right eye: Central corneal haze and intacs



Case #4

8/2021: 64 yr old female referred c/o poor vision / severe night glare both eyes last 22yrs “ever since PRK”. Told she developed “central corneal haze” both eyes and “nothing they could do”

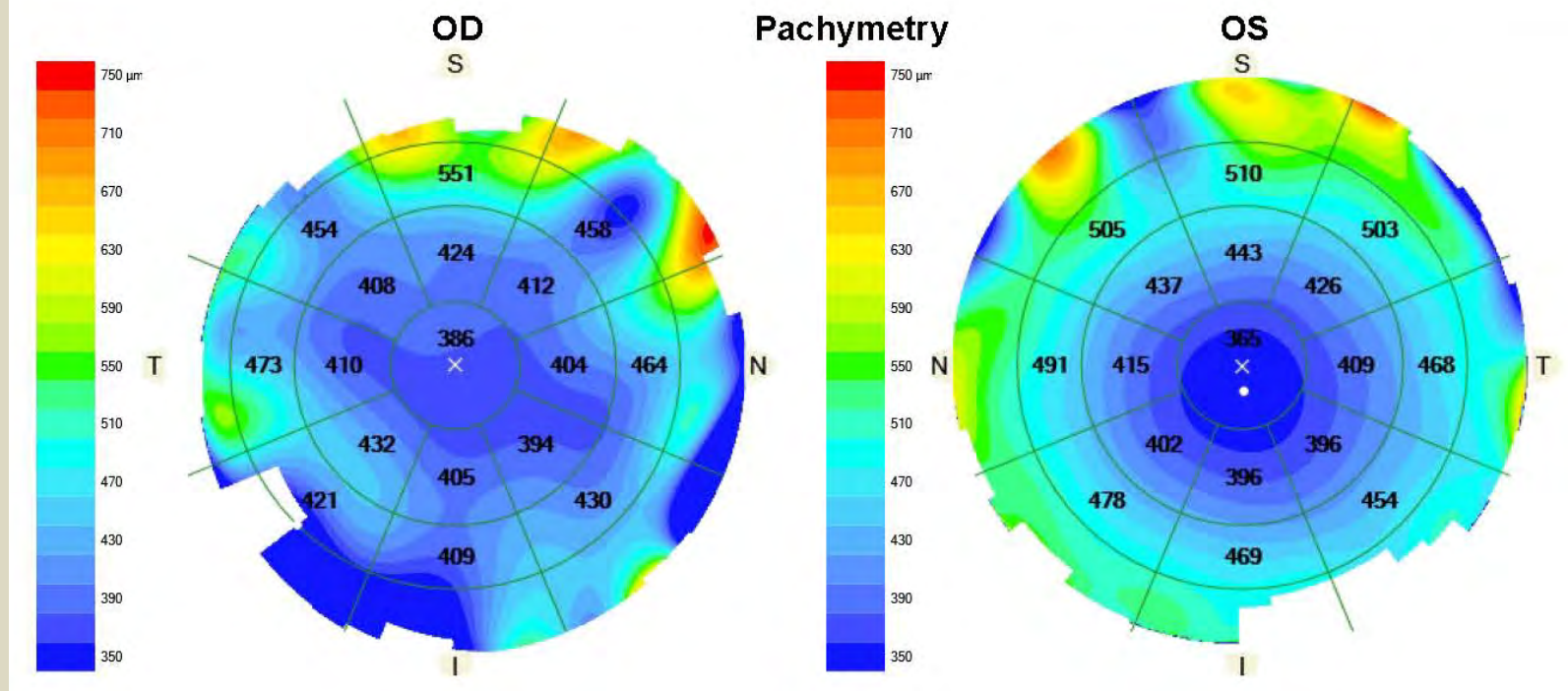
1999 OD undercorrection added paired corneal intacs

1999 PRK high myopia (-13.0 both eyes)

OD: 375u (central cornea thickness after PRK subtracted 150u)

OS 359u (PRK subtracted 150u)

Pachymetry Analysis : Pachymetry



Case #4

3/1/2023 topo below

2/1/2023 OS removed running corneal suture

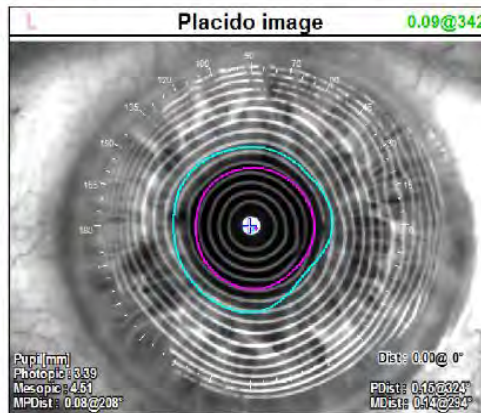
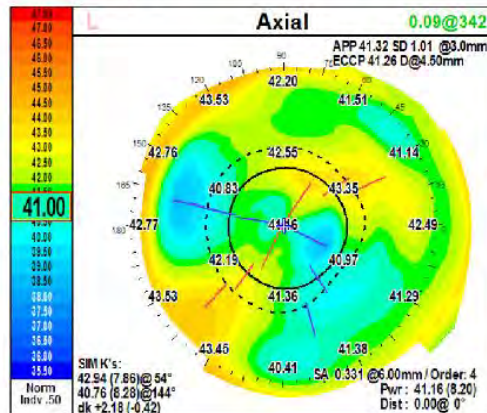
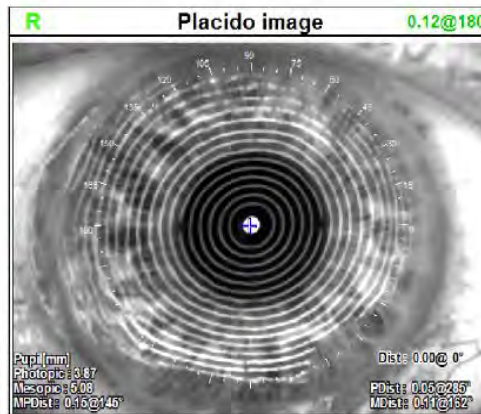
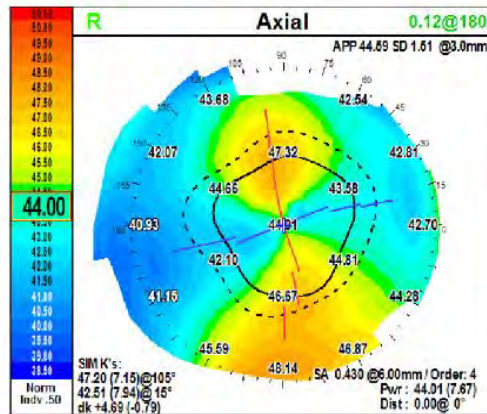
10/2022 OD -14.75+5.5x115 Cat Ext w toric B&L MX60T5.0 6.5D x 106

8/2022 OD removed running corneal suture

6/21/2022 OS DALK 9.5mm bed/9.75mm donor laterality matched nasal marked

11/2/2021 OD Removed intacs/DALK 9.5mm bed/9.75mm donor laterality matched

L	03/01/2023 08:44	Comment	L	Diagnosis	L
R	03/01/2023 08:44		R		R



Right eye

- Uncorrected VA 20/30
- -1.50+1.50 x 135 20/25
- Pt is THRILLED with improvement in visual quality and elimination of glare after 20+ yrs!!!

Left eye

- -12.0+3.5x 55 20/60
- (note: high myopia temporarily restored – will be neutralized after planned cataract extraction with toric IOL)

Richard Erdey, MD