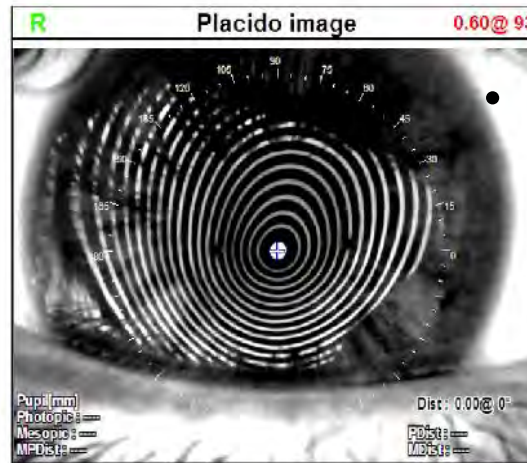
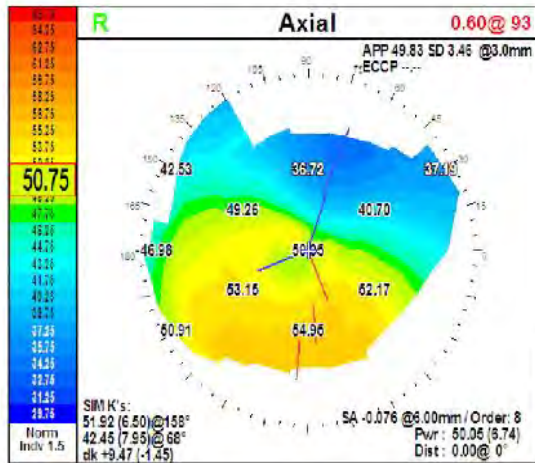
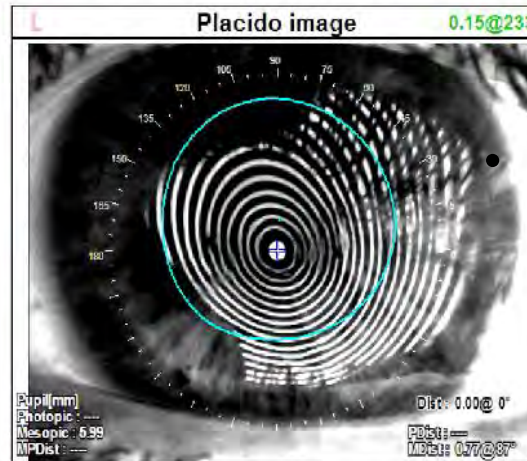
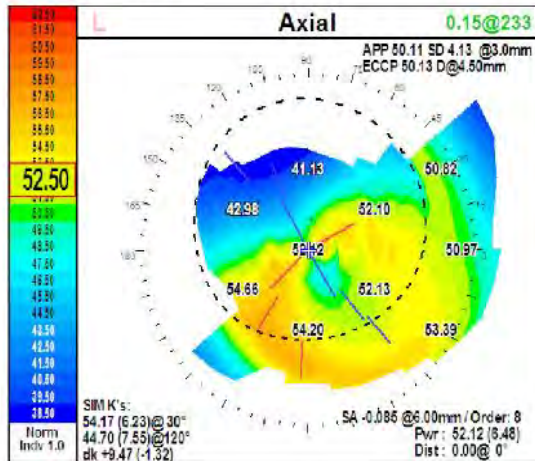


# Case #1: 52 yo m Pellucid Marginal Degeneration (PMD) both eyes

L	06/07/2017 08:59	Comment	L	Diagnosis	L
R	06/07/2017 08:59		R		R



• OD: -8.75+9.0x158 20/50



• OS: -9.0+8.0x30 20/50

Case #1: 52 yo m Pellucid Marginal Degeneration (PMD) both eyes

Right eye: 9/2019 Cataract ext w trulign (crystalens) IOL

3/2019 removed running suture

10/2017 DALK 10.0mm bed/10.5mm donor 24 bite running suture

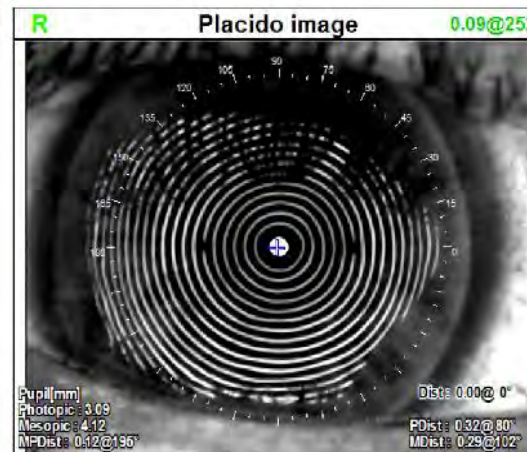
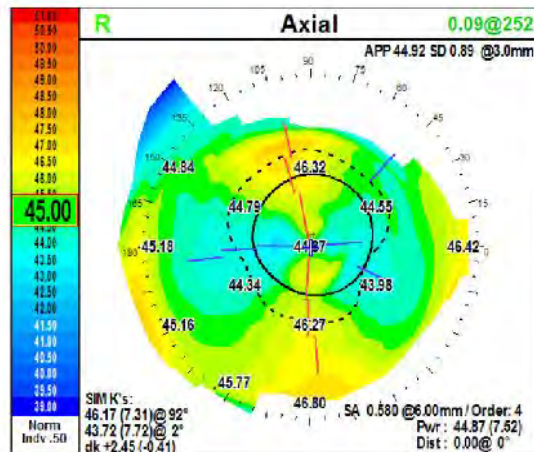
Left eye: 9/2019 Cataract ext w trulign (crystalens) IOL

7/2018 removed running suture

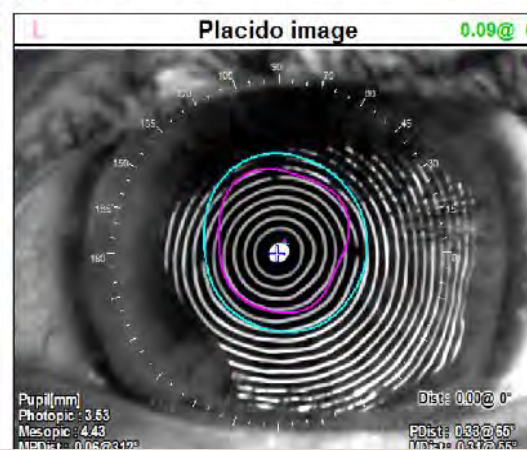
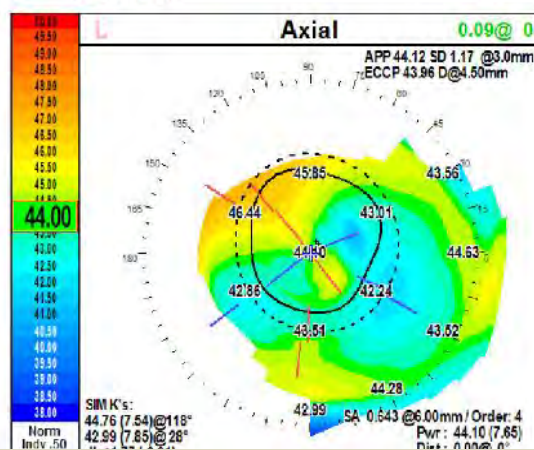
7/2017 DALK 10.0mm bed/10.0mm donor 24 bite running suture

		Technician			
L	02/03/2023 09:55	Comment	L	Diagnosis	L
R	02/03/2023 09:55		R		R

2/3/2023



Uncorrected VA 20/40  
 -1.0+0.25x75 20/20



Uncorrected VA 20/40  
 -0.75+1.5x155 20/20

Richard Erdey MD

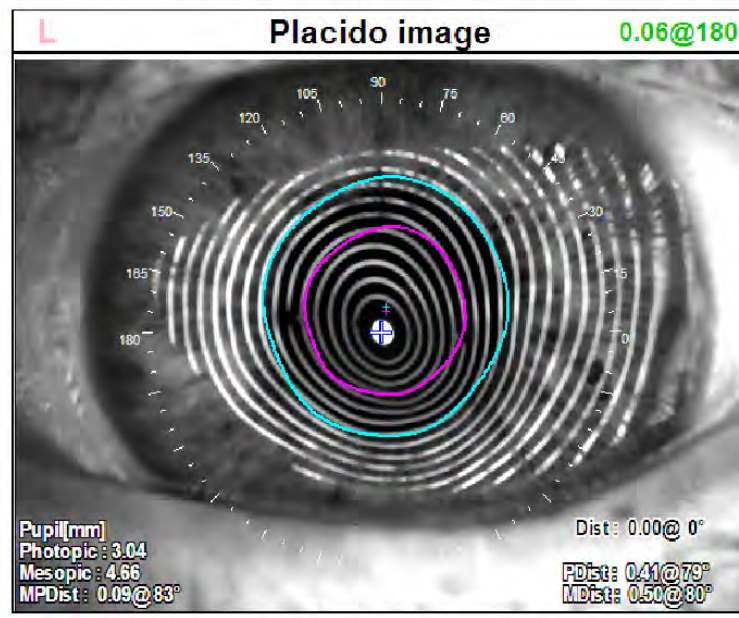
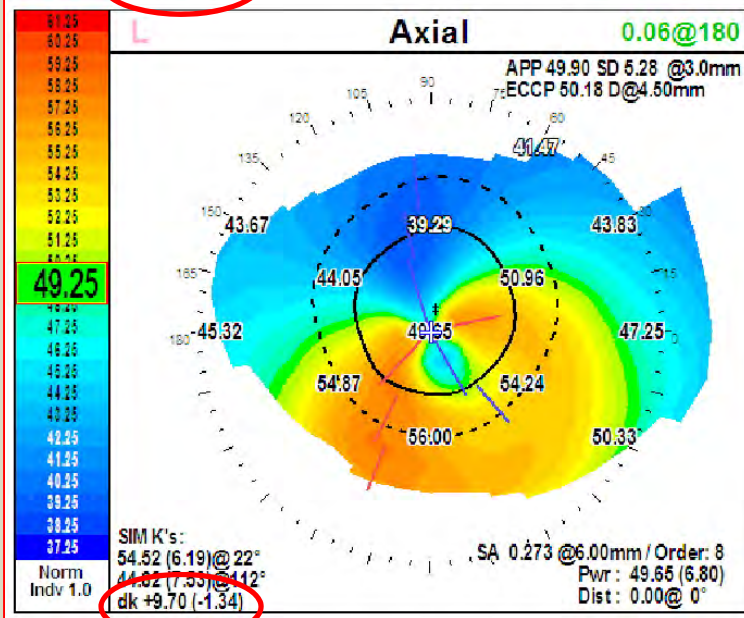
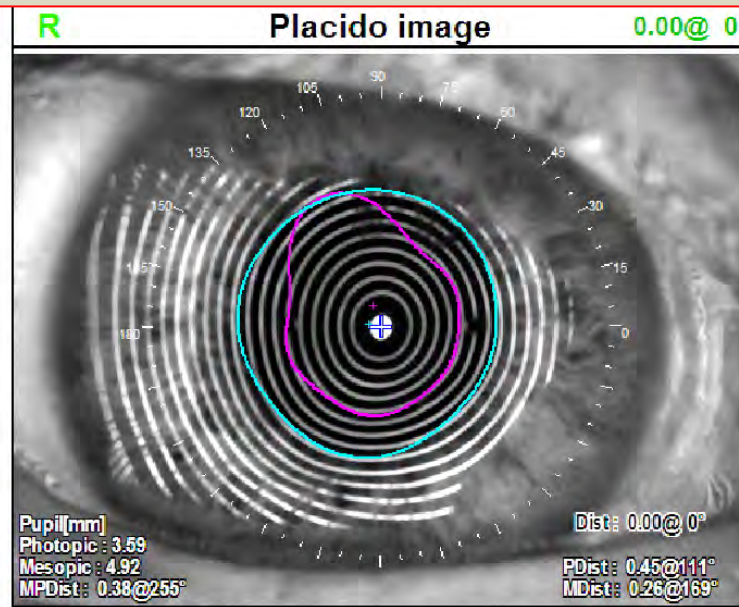
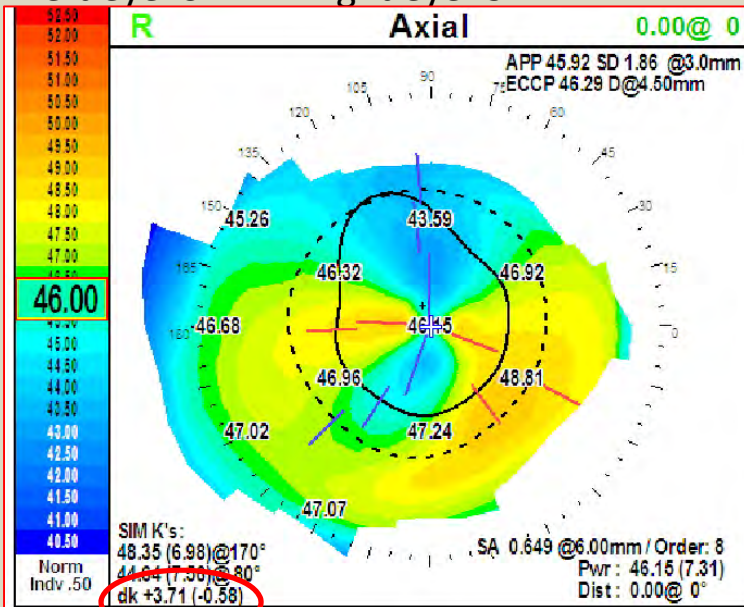


Case 2: 68 yo Pellucid Marginal Degeneration – both eyes

2018 Cornea Cross Linking OS – (performed elsewhere) “failed to improve my vision” (never x-linked OD)

Note: irregular astigmatism both eyes with High Cylinder magnitude

Left eye: 9.7D > Right eye: 3.71D



# Case#2 Pellucid Marginal Degeneration

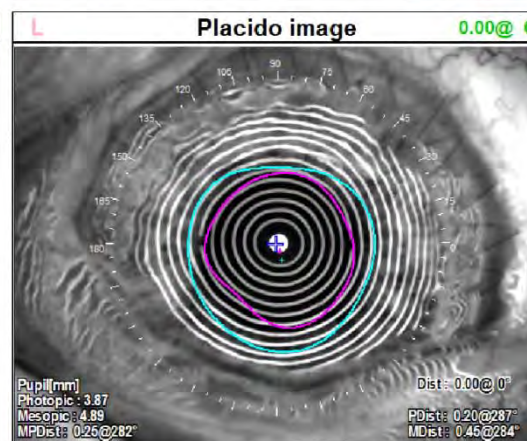
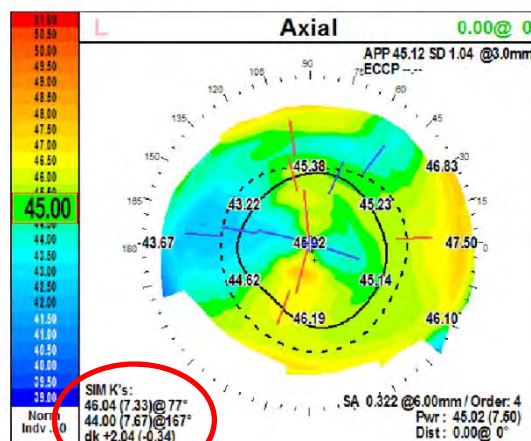
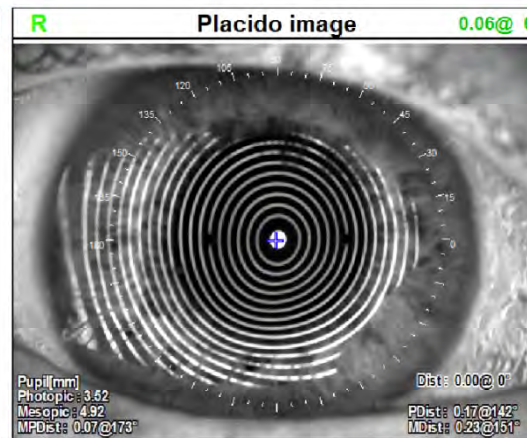
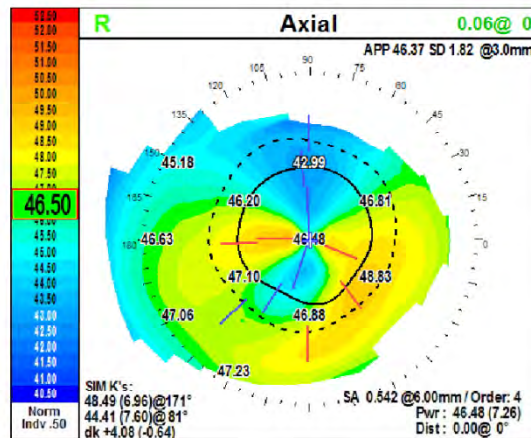
Left:

1/2020 topography below. Running suture “in”

2/2019 Dr Erdey DALK 9.5mm dia.

2018 Cornea Cross Linking – performed elsewhere “failed to improve my vision”

Date	L	01/23/2020 08:50	Comment	L		Diagnosis	L	
	R	01/23/2020 08:50		R			R	





Case#2 Pellucid Marginal Degeneration (PMD) – after Treatment: **VERY HAPPY!**

Right: 4/2021: Dr Erdey: Cylinder 4D (DALK not necessary):Cataract Ext high toric IOL

Left: 5/2022 Topo (below) high suture-out cylinder in DALK graft ... but regular

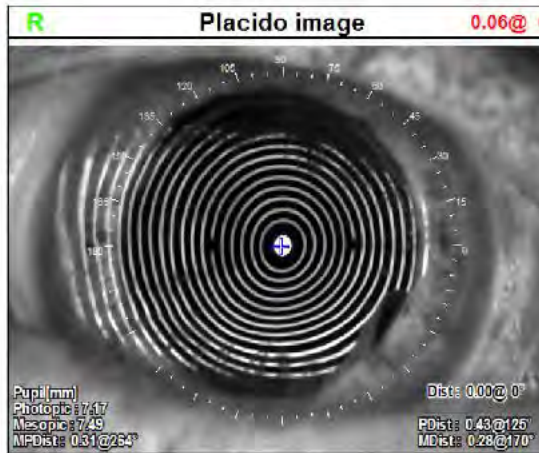
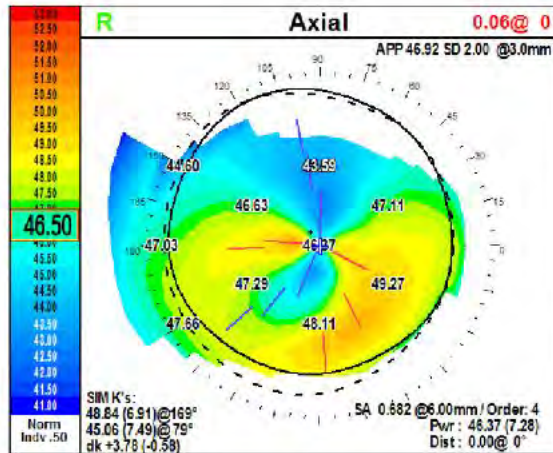
4/2021: Dr Erdey: Cataract Ext high (600) toric IOL x 65.

1/2021: Removed running corneal suture

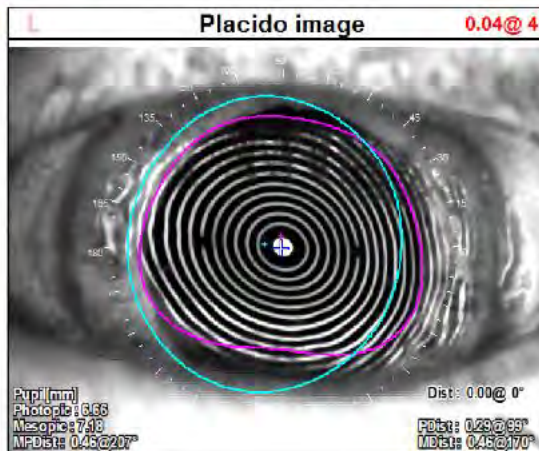
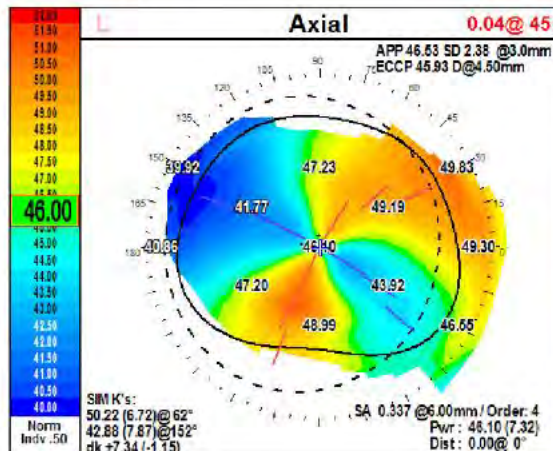
2/2019 Dr Erdey DALK 9.5mm dia. (corneal restoration)

2013 Cornea Cross Linking – performed elsewhere “failed to improve my vision”

L	05/18/2022 09:04	Comment	L	Diagnosis	L
R	05/18/2022 09:03		R		R



• Uncorrected VA 20/25



• Uncorrected VA 20/25  
-0.75+0.5x105 20/25

Richard Erdey MD